

DOI: 10.4172/2472-1905.100031

Autologous Threads and Plasma Exeresis Technique for Total Facial Reconstruction (Internal and External) - HLH Therapy

Tsioumas G. Sotiris*

Diagnostic Clinic and Aesthetic Surgery Ophthalmology, Eye Surgeon-Oculoplastic, Greece

*Corresponding author: Sotiris TG, Private Clinic, Diagnostic Clinic and Aesthetic Surgery Ophthalmology, Eye Surgeon-Oculoplastic, President of Hellenic Society of Aesthetic Medicine and Non-Invasive Surgery, Greece, Tel: +302108825132; E-mail: s_tsioumas@hotmail.com

Received date: September 12, 2017; Accepted date: September 20, 2017; Published date: September 30, 2017

Copyright: © 2017 Sotiris TG. This is an open-access article distributed under the terms of the Creative Commons Attribution License, which permits unrestricted use, distribution, and reproduction in any medium, provided the original author and source are credited.

Citation: Sotiris TG (2017) Autologous Threads and Plasma Exeresis Technique for Total Facial Reconstruction (Internal and External) - HLH Therapy, J Aesthet Reconstr Surg. Vol 3 No. 2:8.

Abstract

Currently, to bring a solution to the aging related factors surgical lifting was the only possible technique. Ptosis is a disease, occurring due to aging that can be corrected by such techniques where the ptosis of the face contour is modified. This technique is known as the renowned facelift. Contemplating the basic assumptions of facial anatomy and surgical lifting, the HLH THERAPY (Hybrid Lifting Homologous) was recommended. An alternative common lifting treatment was introduced where configuration of the face or the component is maintained in a natural and autologous way without altering it in order to restore the youthful look. The treatment is similar to the surgical lifting which does not have open cut procedures as in terms of time and look. There is no risk of fabrication of characteristic or unwanted side effects. A full-face lift also constitutes a blepharoplasty surgery. In this article we will evaluate how we can have a full face lift with blepharoplasty, in a universal way, bloodless, without any cuts or stitches. For the non-surgical blepharoplasty, the technique that is commonly used is known as Plasma Exeresis technique with the Plexr® device.

The Plasma exeresis technique by using the PLEXR® microsurgical device and the autologous threads treatment by using the needle shaping technique and the machine Vibrance are applied and included in the HLH Therapy. The treatment shows the circumstantial development in the thickness of the elastic fibers, which reduce their length and divert their direction from vertical to horizontal (by Needle Shaping), while concurrent with the Plasma exeresis Techniques and the machine Plexr®, we have barrier of sufficient skin. Plexr® do not penetrate the basement membrane and it upholds but also restrains the corneo cells, shrinking of the elastic fibers and at this stage it balances the autologous thread. The co-extensive

activity of these two therapies (autologous threads with Needle Shaping Techniques and sublimation and shrinking of elastic fibers using Plasma Exeresis concurrently) is the structure of the HLH methodology.

We can state that soft surgery applications are the following steps to the ongoing process. The consequences are remarkable within few days of recovery without any anesthetic use.

Keywords: Autologous threads Plexr®; Needle shaping; Sublimation; Homologous; Lipoapoptosis; Non-invasive blepharoplasty; Upper eyelid; Lower eyelid; Natural; Plasma exeresis; Hybrid

Introduction

The total face lifts occupies the 6th place in the ranking according to the latest study by American Aesthetic Plastic Surgery Community and it was found that the most demanding aesthetic surgical method is the face lifts. Face lifting is also known as a type of Aesthetic Surgery and the accurate name of face lifting is facial rectification. For restoration of facial points, the facial simulation practice is used and is also help in raising the emergence of giving account of youth in every patient.

An operation may also include in Face lifting which enhances the fore-head or brow-lift and upper third of the face, the lower third of the face or mid-face lift. By combining with all the above mentioned procedures it can be use and it can also combined with liposuction of cheeks or lower - upper blepharoplasty. By resorting the facial muscle and shrinking the enough skin the face lift is performed beneath the skin in the epidermal musculoskeletal system (SMAS) (Figures 1-10) [1].

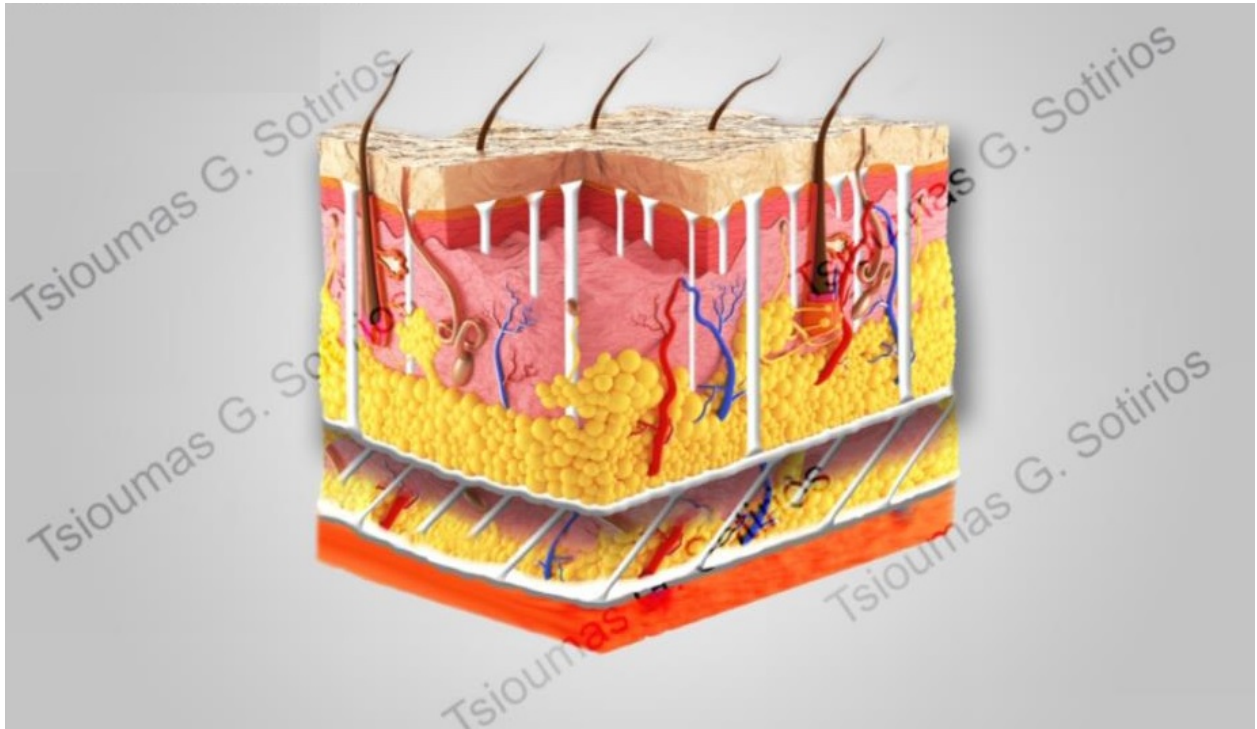


Figure 1: Structure of skin.

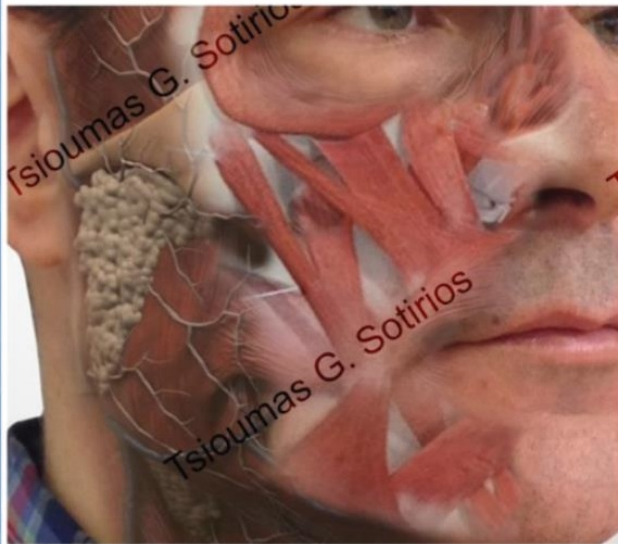

Figure 2: Muscle structure of the face.

All face support through face lifting focuses on the redesign of the Superficial Muscle Aponeurosis System (SMAS) (**Figure 2**). In the so-called SMAS lift, the plastic surgeon restores not only

the skin but also the tissues to its normal position. Restoring the skin and facial tissues we have the inversion of the so-called triangle of youth (**Figure 3**).

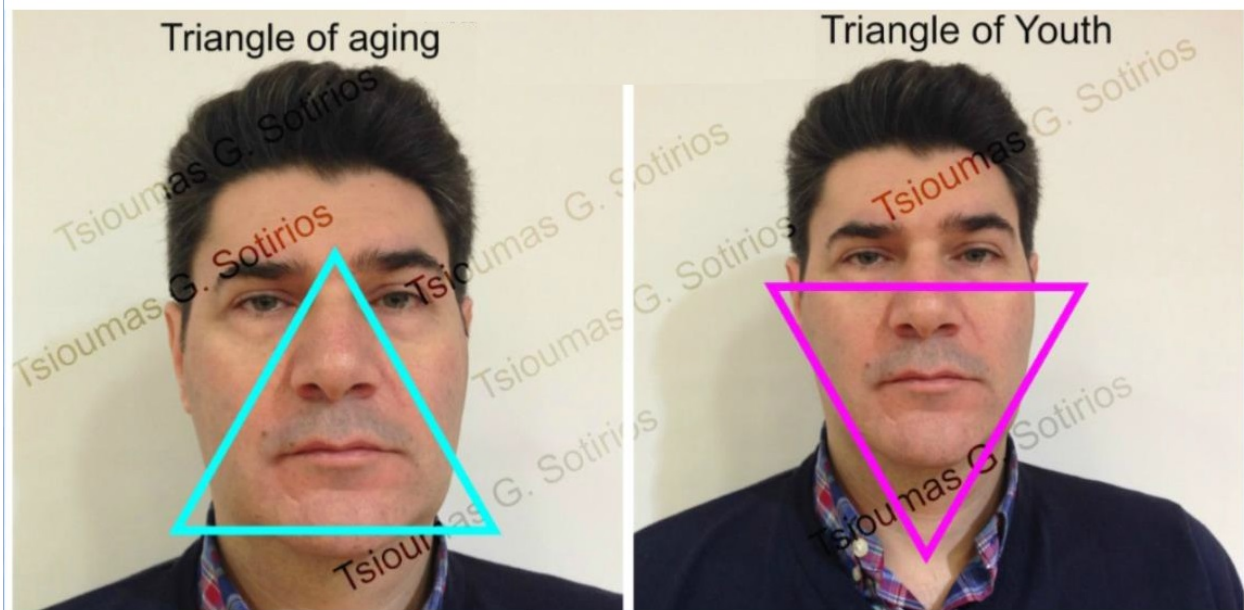


Figure 3: Triangle of Aging youth.

Based on the basic principles of facial anatomy and the theory of surgical face lift, doctor Sotiris G. Tsioumas began the implementation and application of this bloodless HLH Therapy[®] technique. The abbreviation term of HLH Therapy[®] is Hybrid Lifting Homologous. The function of this bloodless HLH Therapy[®] technique is based on the fundamental of facial anatomy and the surgical face lift theory and it was firstly implemented by Doctor Sotiris G. Tsioumas. By using the Plasma Exeresis method and the Plexr[®] device as well as on autologous threads by using the Needle Shaping medical device after five years of experience of the ophthalmologist in non-surgical blepharoplasty and the homonymous method respectively it was inspired and then enforced the latest treatment of natural face lifting and total bloodless [2].

PLASMA EXERESIS & NEEDLE SHAPING is termed as hybrid as it is used for both techniques and they are utilized concurrently during the process of the treatment. The two different techniques are Combinatorial and Concurrent which are used at the same time applied in the same patient.

The result after the utilization of the techniques the term lifting is used as it is total face and neck lift having inverted the direction of the triangle of adolescence from downward direction to upward direction [3-5]. A vital part of the process used is of the autologous thread method so the term Homologous is used. Needle shaping technique used by Dr. Tsioumas G. Sotiris which is based on SMAS's basic theory of tissue repositioning. He regenerated real aged tissue and removes it by transfer the frequency and control of the facial elastic fibers when it is taken by an organism without involving surgically and when it given to itself then it is known as autologous technique. By Needle Shaping technique the real aging elastic fibers are achieved and new ones are given and are recreated.

HLH Therapy[®] the new therapy which is based on its plasma (PLEXR[®]) and autologous techniques (NEEDLE SHAPING) concurrently and it can be utilized without panic, without creating any difficulty with autoimmune diseases to population and also with the people who is suffering from cancer and diabetes [6]. The total face lifts occupies the 6th place in the ranking according to the latest study by American Aesthetic Plastic Surgery Community and it was found that the most demanding aesthetic surgical method is the face lifts. Face lifting is also known as a type of Aesthetic Surgery and the accurate name of face lifting is facial rectification. For restoration of facial points, the facial simulation practice is used and is also help in raising the emergence of giving account of youth in every patient [7]. An operation may also include in Face lifting which enhances the fore-head or brow-lift and upper third of the face, the lower third of the face or mid-face lift. By combining with all the above mentioned procedures it can be use and it can also combined with liposuction of cheeks or lower-upper blepharoplasty. By resorting the facial muscle and shrinking the enough skin the face lift is performed beneath the skin in the epidermal musculoskeletal system (SMAS).

The abbreviation term of HLH Therapy[®] is Hybrid Lifting Homologous. The function of this bloodless HLH Therapy[®] technique is based on the fundamental of facial anatomy and the surgical face lift theory and it was firstly implemented by Doctor Sotiris G. Tsioumas. By using the Plasma Exeresis method and the Plexr[®] device as well as on autologous threads by using the Needle Shaping medical device after five years of experience of the ophthalmologist in non-surgical blepharoplasty and the homonymous method respectively it was inspired and then enforced the latest treatment of natural face lifting and total bloodless.

PLASMA EXERESIS & NEEDLE SHAPING is termed as hybrid as it is used for both techniques and they are utilized concurrently during the process of the treatment. The two different techniques are Combinatorial and Concurrent which are used at the same time applied in the same patient. The result after the utilization of the techniques the term lifting is used as it is total face and neck lift having inverted the direction of the triangle of adolescence from downward direction to upward direction. A vital part of the process used is of the autologous thread method so the term Homologous is used. Needle shaping technique used by Dr. Tsioumas G. Sotiris which is based on SMAS's basic theory of tissue repositioning [8]. He regenerated real aged tissue and removes it by transfer the frequency and control of the facial elastic fibers when it is taken by an organism without involving surgically and when it is given to itself then it is known as autologous technique. By needle shaping technique the real aging elastic fibers are achieved and new ones are given and are recreated.

HLH Therapy® the new therapy which is based on its plasma (PLEXR®) and autologous techniques (NEEDLE SHAPING) concurrently and it can be utilized without panic, without creating any difficulty with autoimmune diseases to population and also with the people who is suffering from cancer and diabetes. The patient must enter a sterilized operating room in surgical techniques of upper eyelid with a scalpel, a radio

scalpel or laser, and then it is anesthetized with xylocaine adrenaline injection and this is followed by having laceration and joints. Another purpose of this study is to establish that the technique of non-surgical blepharoplasty with Plexr without the use of any anesthesia and sterilization it facilitate the medical treatment of patient (using only anesthetic cream) and after treatment the patient leaves without laceration and joints it is the most important. In cases of eyelid surgery the basic convenience point, the effective non-interfering method that grant the operator to appetite the patient at any time during the archives to exposed his eyes, displaying manner of skin that still demand to be consider and escape going after restrained gradual and actions that may have cost image lagofthalmos or extra opening of the eyes is the Plexr. It is also the ideal choice to escape further difficulty of the patient with alteration in his private clinic in infinitesimal time the recognizable preference of Plexr as to any curative surgery. Histological research from the University of Cheti and the University of Athens (Department of Pathology-Anatomy) also demonstrated that the spots of Plexr is not capable to cross the basement sheath of skin, but make shrinking of the elastic fibers and collagen type III is created after one month. The patient escapes surgery so Plasma Exeresis method is a very adequate it is also having the same effect with cheaper cost and also for most logical aspects (Figure 4).

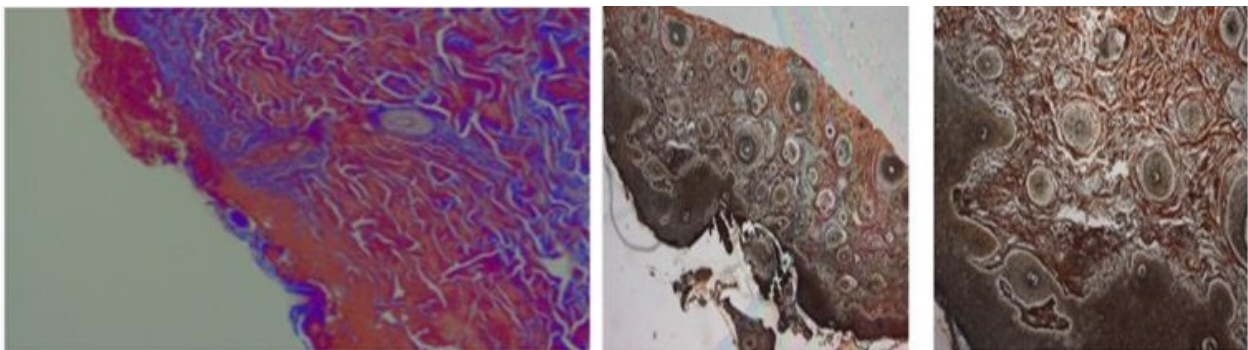


Figure 4: Regions shows the Plasma Exeresis application on skin which not only reconstructed but created type collagen III after its application.

Methodology

The latest HLH Therapy by Tsioumas Sotirios® the sample of patients that was used to implement technique include 10 women's, age between 50-80 years old, non-smoker and the people who had not gone through any operations in the past through any surgical lifts. By taking photographs, treatment process started with the doctors. At 45 and 90 degree angle the doctor started capturing photographs of the patient's faces, enface and profile. They applied anesthetic cream to only those particular areas after that the doctor moves on with the complete antiseptis in the area of the face and neck. The reaction of the anesthetic cream is observed after waiting for around an hour. The anesthetic cream was again applied within an hour. The patient is ready to start the treatment after an hour. Hinderer lines act as doctor's guides that follow the two main lines. NEEDLE SHAPING electrode of the device

was hold by the patience and by naked hand the second electrode was hold by the doctor. At this moment the direction of the needle changes with outwards direction by pulling the acupuncture needle upwards by the doctor. At this point an external slight zones and wrinkles are generated from the extra of skin. The acupuncture needle revolves and shifts upwards through the doctor-patient electrodes by the doctor. The energy from the doctor's hand to the needle and from the needle into the elastic fibers at that moment. Elastic fibers have been change by this and so, their quality will enhance. The doctor used the microsurgical device Plexr® together with his second hand and at the same time it sublimates the extra tissue that is generated. At the point where the doctor has marked them, with sublimation the disappearance of the wrinkles, wrinkles at estrofleion zones as well as the adjusting of the elastic fibers (autologous threads) is accomplis

h. An external superficial zone flattened and the elastic fibers to the right point are sealed (**Figure 5**).

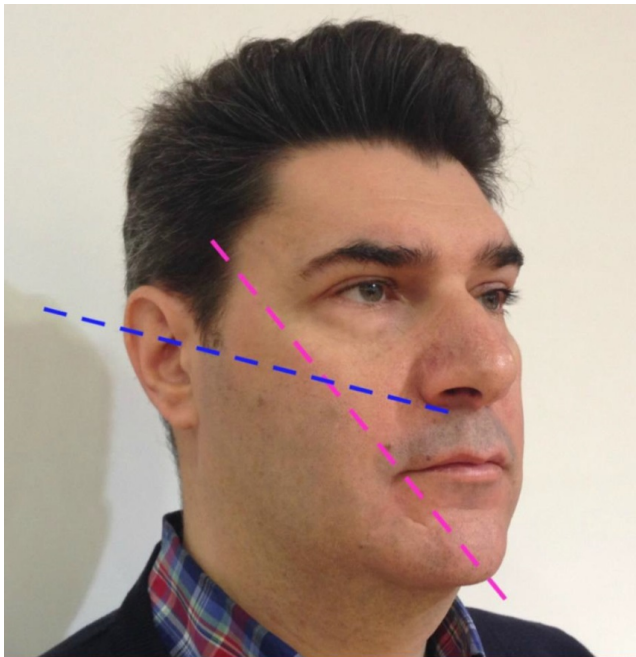


Figure 5: Hinderer Lines.

As soon as the hinderer lines are designed, the first phase of the treatment begins. The doctor is using the large diamond acupuncture needle and inserts the first needle into the skin (**Figure 6**).

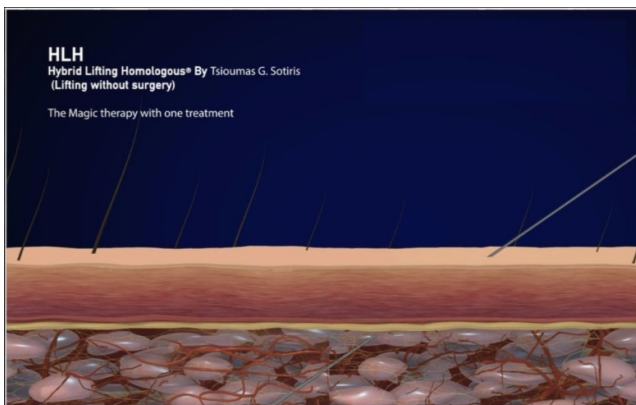

Figure 6: Inserting the acupuncture needle.

The patient holds an electrode of the needle shaping device the doctor holds the second electrode with his naked hand. At this point the doctor pulls the acupuncture needle upwards and turns the needle with outwards direction. At this point, external superficial zones and wrinkles are created from the excess of skin. At the same time that the doctor revolves and moves the acupuncture needle upwards, through the doctor-patient electrodes, the energy is delivered from the doctor's hand to the needle and from the needle into the elastic fibers (**Figure 7**).

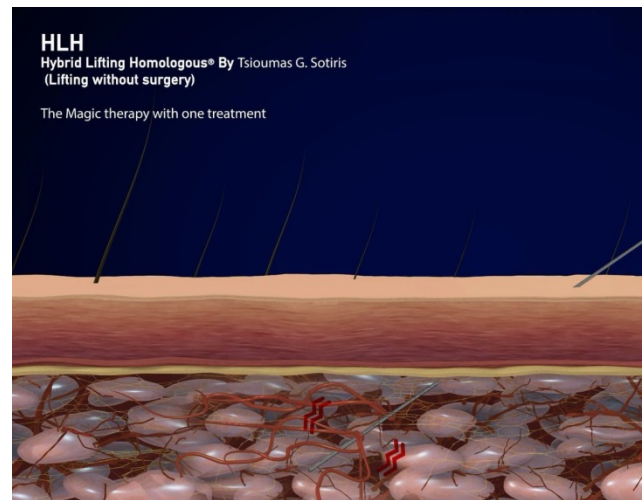


Figure 7: Vibration and catching of the elastic fibers.

These electrodes create micronoses that penetrate the elastic fibers. What happens internally is that the elastic fibers vibrate and engage (like sticking) on the acupuncture needle (**Figure 8**).




Figure 8: Elastic fibers sticking on the needle.

By pulling upwards and outwards, the elastic fibers follow the same upward course. At the same time, due to the sticking on the acupuncture needle the elastic fibers become denser, more compact, thick and upwards directed (**Figure 9**).

At this point the elastic fibers have been re-positioned and their quality improved. The doctor with his second hand, simultaneously using the microsurgical device Plexr®, sublimes at the same time the excess tissue that is created. With sublimation, what are achieved are the disappearance of the wrinkles, wrinkles at estroflektion zones, as well as the fixing of the elastic fibers (autologous threads) at the point where the doctor has delimited them. We have flattened the external superficial zones and locked the elastic fibers to the right point (**Figures 10-14**) [9].

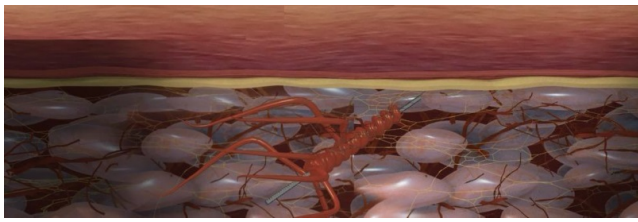


Figure 9: Thickness of elastic fibers.

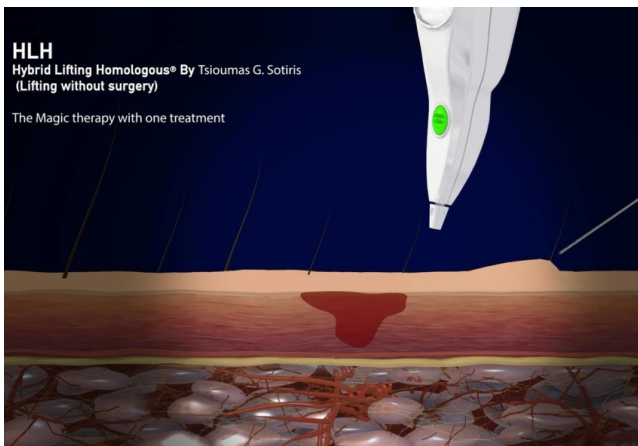


Figure 10: Sublimation of the epidermal and locking the elastic fibers to the right point.

Once the sublimation finished due to the sealing of the fibers the doctor excludes the acupuncture needle. The retraction the needle is ejected which produce some pain. Because of sublimation some crusts are created that fall down on average 5 days after treatment the areas where HLH therapy[®] is applied. The skin causes slight irritation which disappeared over the next 20-30 days by applying an anaplastic cream after the crusts fell down. The patient just after the treatment used a special protective makeup with a high sun protection factor and he can shortly leave the clinic. We should mention at this moment that no antibiotics will be used after the treatment, any bandages or total anesthesia. The treatment make really safe because all of these components and when it compared to a traditional surgery as it diminishes its cost. At this point, we should mention that after the treatment no antibiotics will be needed, no bandages or total anesthesia. All of these elements make the treatment absolutely safe and of course it reduces its cost compared to a traditional surgery.

As far as concerned all the patients accepted antiseptis as it is the methodology for non-surgical upper eyelid blepharoplasty and then their faces was captured before the treatment and in order to observe the changes after the treatment their profile were created. The next step was to wait for 30 minute until the cream react after applying the anesthetic cream and so the patient won't perceive any pain while the treatment is carried on. The technique was applied first on the right eyelid and then on the left. The area where

there is extra skin is sublimated we did not penetrate wrinkles but field of extra skin. The machine should not touch the skin for producing as ionization gas are necessary we leave little area of fresh tissue so while the micro spots were exit. In each term 30% of the extra skin we sublimated.

In cases of the lower eyelid non-surgical blepharoplasty we need to notice that we can do Plexr[®] only in cases of dermatochalasis or small fat bags. The procedure will be little different if we have medium or big fat bags because firstly we need to liquefy the fat (through O.f.f machine for lipoaptosis by taking the use of acupuncture needles and Needle Shaping – Autologous Threads or through injectable solution vitamin C) and then move on with Plexr[®] method. We need to mention the two categories of skins before moving on to the photo presentation of the HLH METHOD[®] that we may found during the process. We move directly to the HLH METHOD[®] as we analyze above if our patient has quite thin skin, without any fat but in the case if our patient has a lot of fat areas and his skin is thicker and fatty we add one more step in the method. This step is the wells know method of Needle Shaping–Autologous Threads which combined with the machine O.f.f – machine of lipoaptosis with acupuncture needles. This additional step is very important because firstly we need to form the lipolysis through O.f.f (machine of lipoaptosis with acupuncture needles) and after that the skin is ready to accept the HLH METHOD[®]. In common words if our patients has thick skin and many fat areas we start our session by Needle Shaping method and Off and then afterwards we move on to the HLH METHOD[®].

Following is a photographic material indicating the step by step methodology of HLH THERAPY.

Results

The results obtained from this new treatment are actual and extremely remarkable. The patient after observing the difference in his face leaves the clinic with very relief with an energetic sensation of pulling and tightening. This latest treatment is based on techniques which are very successful effects which are observed more than ten such as Plasma Exeresis (Plexr[®]) and Needle shaping.

Firstly, after one month of the therapy there is formation of collagen type III in sublimation areas. The use of Plexr[®] has proven for the Past histological examinations. Secondly, through the Plasma Exeresis technique and the Plexr[®] machine the complete sublimation of the keratinocytes was done. The formation of autologous threads as well as the direction shifts was observed and by the Needle Shaping technique the quality of the elastic fibers was achieved. Again, freshly new elastic fibers are regenerated after 28 days it was showed by histological analyzes for Needle Shaping. The shorter and thicker like elastic fibers were observed. Through the needle shaping and Plexr techniques we have the sublimation of extra tissues concurrently in together with fascinating the elastic fibers and the most necessary consequences is their shrinking. We shrink the elastic fibers in HLH Therapy[®], we made it thicker, arrange them, change their direction from vertical to

horizontal, through Plexr we make the fasciation of the autologous threads at the same time.

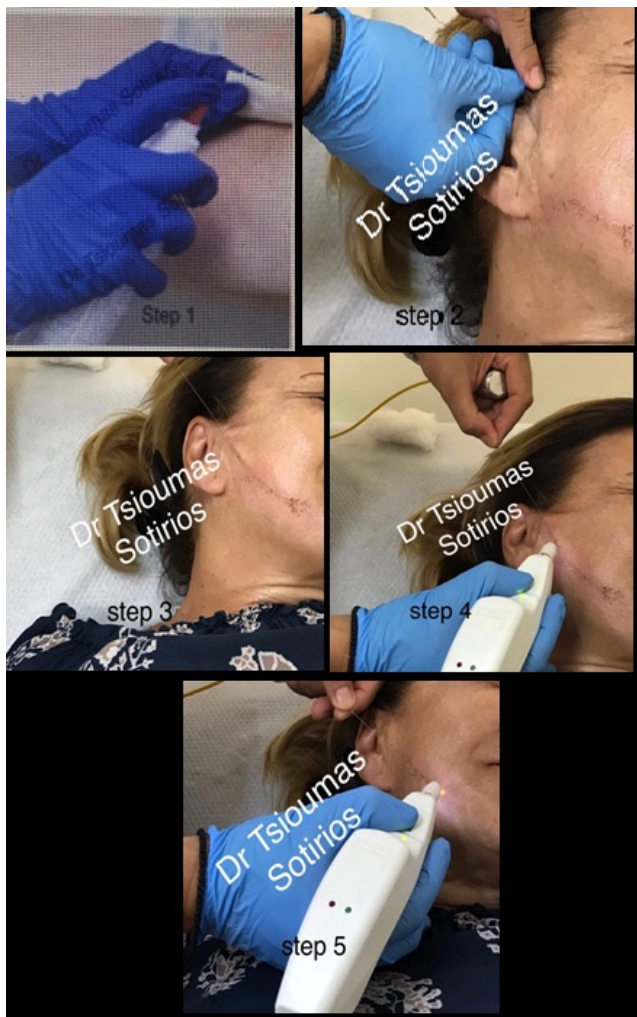

Figure 11: Photo presentation of HLH THERAPY® STEP.

All this give the effect of modifying the overall face. In HLH therapy® due to the fact we have a combine form of different tools and techniques; that we can involve and bring results to the space that could not be involve with the sword like the space in the crow's feet and neck. As concerned the patient's with psychosomatic balance is not dominate to any process of total stupor that create complexity so he feels fearless, he feels safe, and he can come precisely to his normal life.

But the entire patient can able to observe directly the conclusion without any wait and duration of high rehabilitation times. As Keloid hypertrophic scars we have no complexity during rehabilitation, numbness from nerve section and facial deformities. During or after treatment either none of the 10 cases experienced any complexity.

As far as concerned, the productivity of the non-surgical upper eyelid blepharoplasty via Plexr® is compared with classical upper eyelid surgical blepharoplasty the outcomes were remarkable without any joints and lacerations, ectropion

and entropion, slanted eyes, lagophthalmos and alternative complexity. It takes only a short duration of time to get recovered (7-15 days) and it also allows the patients to come back to their normal life after treatment. The total results reveal that Plexr® as the method for non-surgical blepharoplasty has dominance over the surgical method due to the low financial conclusion, the patient can used this treatment repeatedly as many times as he or she want, there are no complexity, no variation in their appearance. According to the scientist engaged in aesthetic medicine particularly need not their own high Specificity [10].

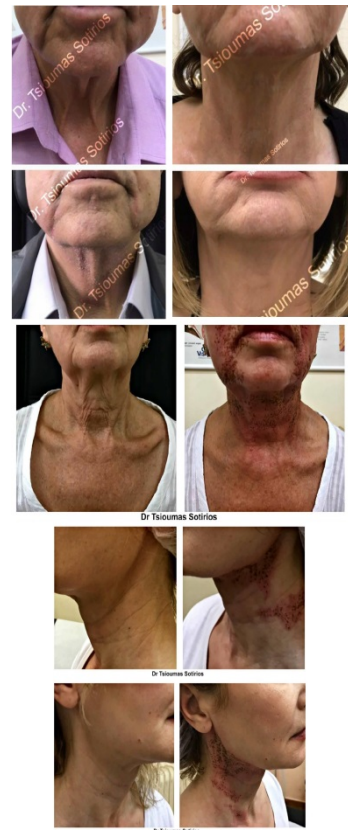

Figure 12: Photo presentation of HLH METHOD® before and after results.

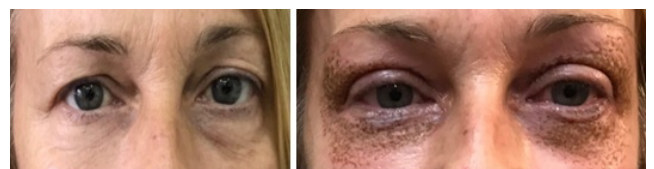

Figure 13: Photo presentation of before and after of non-surgical blepharoplasty.

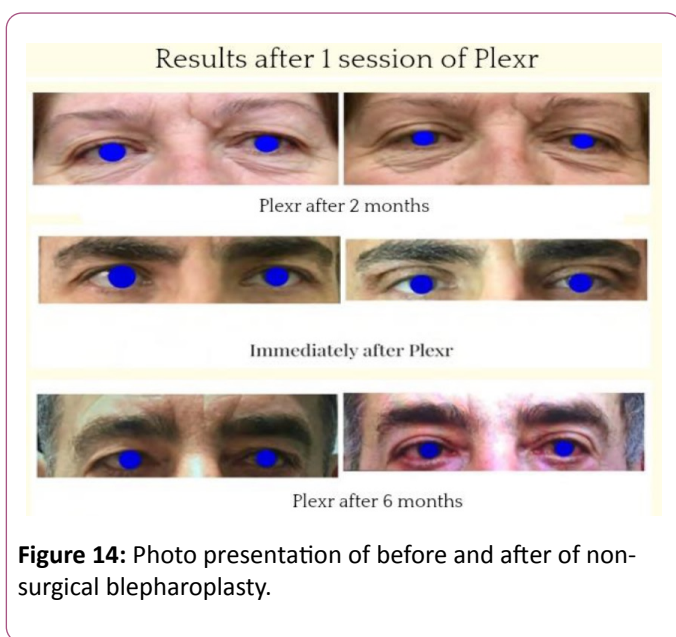


Figure 14: Photo presentation of before and after of non-surgical blepharoplasty.

Conclusion

The demand of the physician is to use latest improved innovative non-invasive methods to patients who cause less pain and cheaper cost but also the demand of the patient for cosmetic procedures that avoided by them previously for fear of surgery. The most significant advantage of Plasma Exeresis and all the autologous therapies that were discussed above is security that it provided to the patient on disappointing effects. A new method i.e. Plexr is reaching more patients and due to the rapid recovery, lack of pain, no joints and the results are remarkable. The patient feel safe after getting advice in briefly by the doctor and many of patients decide to do their application immediately after updating, unlike surgery that there must be some arrangements before go through.

The most sceptical patients they recommended the methods to the people who are seeing for inventive non-invasive methods for Aesthetic Medicine after their first session.

Now the trend has been changed in all fields including medicine and is directed towards the natural, autologous and without blood. Based on the latest trend and the need for the more natural and without blood results, there is a need for treatments that do not desire lengthy period to get recovered,

treatments that do not form fear and are not financially unbearable. HLH Therapy[®] has been generated by combination with both non-surgical upper or lower eyelid blepharoplasty. The scientific documentation is the next step in the treatment through new histological examinations that will be carried out in the following period and will be exclusively about HLH therapy[®].

References

1. Sotiris G, Irini G, Ioannis N (2014) Noninvasive Upper Blepharoplasty In Relation To Surgical Blepharoplasty. *Pinnacle Medicine & Medical Sciences* 1: 436-440.
2. Sotiris TG, Nikolaos G, Irini G (2014) Plexr: The Revolution In Blepharoplasty. *Pinnacle Medicine & Medical Sciences* 1: 423-427.
3. Sotiris TG, Dimitris V, Nikolaos G (2015) Clinical and Histological Presentation after Plexr Application, Needle Shaping (Vibrance) and O.F.F. *Pinnacle Medicine & Medical Sciences* 2: 522-530.
4. Sotiris TG, Ioannis C, Apostolos P (2015) The Efficiency of Vibrance (Needle Shaping) and O.F.F (NonSurgical Dermal Ablative Treatment) On Body Reshaping. *Pinnacle Medicine & Medical Sciences* 2: 506-509.
5. Stamatina G, Sotiris TG, Aglaia V (2015) Plexr in Acne Treatment. *Pinnacle Medicine & Medical Sciences* 2: 482-486.
6. Sotiris TG, Ioannis C, Irini Z (2015) The Induction Of Lipolysis using the Machine of O.F.F (bags under the eyes) and the application of Needle Shaping Technique using the Vibrance Machine (Tear through). *Pinnacle Medicine & Medical Sciences* 2: 445-448.
7. Sotiris TG, Ioannis C, Anastasia VL (2015) Comparison of The Efficacy of Injectable Hyaluronic Acid Versus Needle Shaping (Vibrance) and O.F.F (Onde Flusso Frazionato) for The Aesthetic Treatment of the Face. *Pinnacle Medicine & Medical Sciences* 2: 441-444.
8. Gloustianou G, Sifaki M, SotirisTG, Dr. Vlachodimitropoulos, Scarano A (2016) Presentation of Old and New Histological Results After Plasma Exercises (Plexr) Application (Regeneration of The Skin Tissue With Collagen III). *Pinnacle Medicine & Medical Sciences* 3: 983-990.
9. Tsioumas G S, Georgiadis N, Georgiadou I (2017) The Gas Ionization by Plasma Technology for Noninvasive Techniques in Oculoplastic. *JOJ Ophthal* 2: 555584.
10. Sotiris TG (2017) New Treatment with Plasma Exeresis for Non-Surgical Blepharoplasty. *EC Ophthalmology* 5: 156-159.