

Elastic Conization and Suspension Improves the Appearance of Breasts with Implants

Sergio Capurro*

Ospedale Policlinico San Martino, Centro di ricerca medica, Genoa, Italy

*Corresponding author: Sergio Capurro, Ospedale Policlinico San Martino, Centro di ricerca medica, Genoa, Italy, E-mail: sergio.capurro@hotmail.it

Received date: March 1, 2022, Manuscript No. IPJARS-22-13069; **Editor Assigned date:** March 3, 2022, PreQC No. IPJARS-22-13069 (PQ); **Reviewed date:** March 17, 2022, QC No. IPJARS-22-13069; **Revised date:** March 23, 2022, Manuscript No. IPJARS-22-13069 (R); **Published date:** April 1, 2022, DOI: 10.4172/2472-1905.100148

Citation: Capurro S (2022) Elastic Conization and Suspension Improves the Appearance of Breasts with Implants. J Aesthet Reconstr Surg Vol.8 No. 3:27

Abstract

Background: Breasts with implants frequently have an unnatural appearance, which can be improved by means of a simple technique.

Methods: The elastic suture (Elasticum EP4, Korpo) mounted on the two-tipped Jano needle conizes and suspends the breasts through only two incisions of a few millimeters.

Results: The effect of implanting the elastic conizing and suspension threads is immediately visible; the breasts look more natural and attractive.

Conclusion: Elastic conization is a simple procedure that makes breasts with implants look more natural. Drooping breasts can be lifted and suspended to the thoracic subcutaneous tissue by means of an elliptical elastic suture.

Keywords: Mastopexy of breasts with implants; Elastic suture; Two-tipped needle; Additive mastopexy

Introduction

Conizing breast that have implants corrects the artificial appearance created by additive mastopexy, making them look more natural. This procedure also eliminates the appearance of a “ball in a sock” (Figure 1). If the breasts are still ptotic after the procedure, they can be lifted by means of an elastic suspension thread.

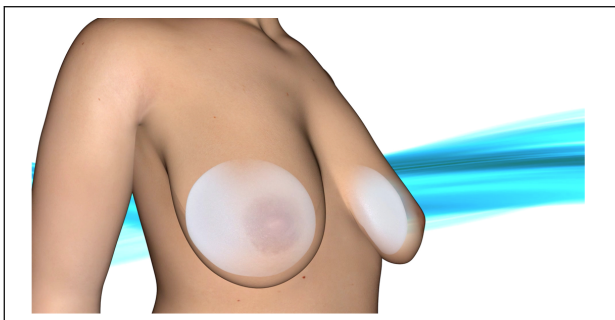


Figure 1: Heavy breast implants detach from the chest wall, creating the “ball in a sock” appearance.

Materials and Methods

Conization and suspension of the breasts is performed by means of the elastic thread (Elasticum EP4, Korpo) mounted on the two-tipped Jano needle. This new elastic surgical thread, which is made of polyester-coated silicone and mounted on a Jano needle [1-3], is used to create one or two circles, to conize the breast and point the apex [4-6]. If the breasts are still ptotic, further elastic thread is implanted along an elliptical pathway; this suspends the breast to the thoracic subcutaneous tissue. The elastic thread is impalpable and, once colonized by connective cells, becomes an “integrated ligament”.

Preoperative design

A circle is drawn at a distance of ½ cm to 2 cm from the areolar margin; the thread implanted along this circular pathway can shrink the areola or conize the apex of the breast. A second circle, drawn at 5 cm-7 cm from the nipple, marks the pathway of the thread that will push the implant into contact with the chest wall (Figure 2). A tunnel is then drawn (Figure 3). Conization is performed through an 8 mm skin incision in the areolar margin. If the breasts are ptotic, an ellipse is drawn across the most prominent part of the lower quadrant of the breast and, in the upper part, across the thoracic subcutaneous tissue at the border with the skin of the breast.

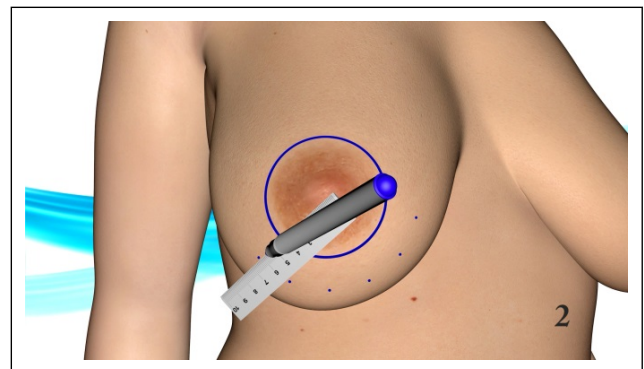


Figure 2: The circular pathway of the thread that conizes the breast is drawn. This thread will bring the implant into contact with the chest wall.

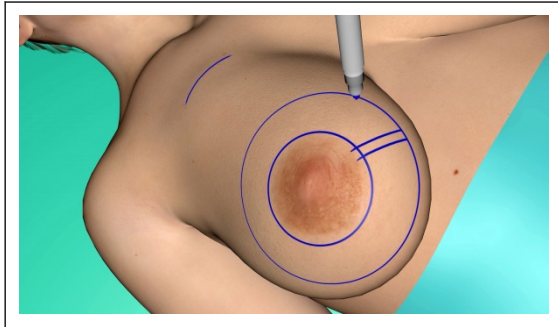


Figure 3: The pathway of the subcutaneous tunnel is drawn. Above, a line marks the transition from breast skin to thoracic skin.

Local anesthesia

Local anesthesia is performed along the pathway where the elastic thread is to be implanted. To 500 ml of saline solution, we add 25 ml of 2% mepivacaine and 1.5 mg of epinephrine. Once anesthesia is complete, the procedure begins.

Surgical procedure

An 8 mm skin incision is made at the areolar margin. Scissors are used to dissect the subcutaneous tissue and to create a tunnel at a depth of about 5 mm, the depth at which the elastic thread is to be implanted (Figure 4). This tunnel extends a few centimeters beyond the line of the external circle. The circle is drawn approximately 6 cm from the nipple. Variations are possible, depending on the size of the breasts.

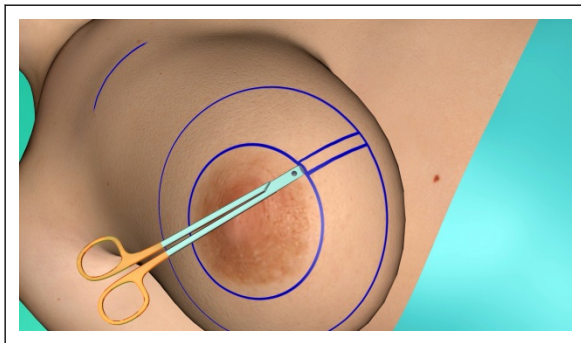


Figure 4: Scissors are used to dissect the subcutaneous tissue and create a tunnel at a depth of approximately 5 mm.

The operator inserts the retractor into the tunnel, followed by the two-tipped Jano needle.

The needle partially emerges on the line (Figure 5) and is extracted until about 5 mm of the posterior tip remains in the tissues; it is then rotated and follows the preoperative design.

The operator moves the Jano needle slightly up and down to ensure that its pathway is at the right depth. If the needle is too superficial, it must be drawn back and passed through at a greater depth, otherwise the skin will be intro lected. The elastic thread is pulled through and placed under tension. As always, a Klemmer is attached to the end of the thread. The two-tipped needle partially emerges along the line drawn preoperatively. When about 5 mm of the posterior tip remains in the tissues, the Jano needle is rotated and continues its pathway along the preoperative design. When the Jano needle reaches the tunnel, it is partially extracted and, with the help of the retractor, rotates and emerges from the periareolar incision (Figure 6). The retractor remains in the tunnel to enable the two ends of the elastic thread to be correctly knotted.

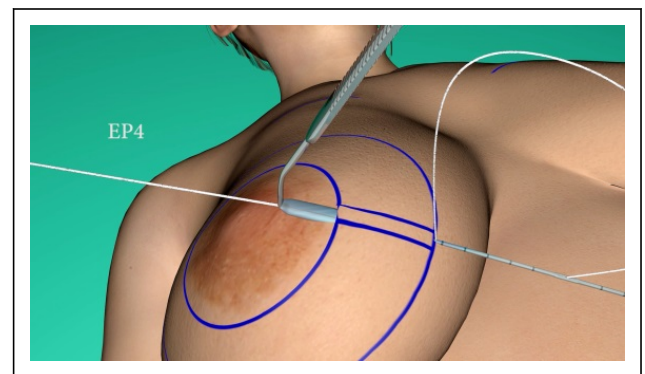


Figure 5: The two-tipped needle partially emerges on the line and is extracted until about 5 mm of the posterior tip remains in the tissues.

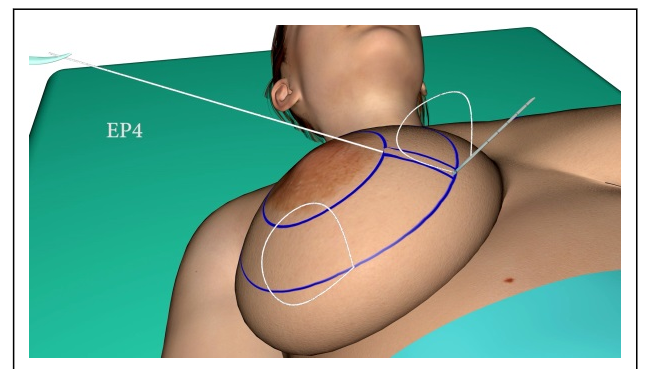


Figure 6: Having reached the tunnel, the Jano needle is partially extracted and rotated. With the help of the retractor, it emerges from the small periareolar incision.

The first encirclement of the breast with the elastic thread is complete. Elastic conization of the breast pushes the implant into contact with the chest wall (Figure 7). If the two-tipped needle comes out during its passage, the elastic thread must be extracted and reimplanted.

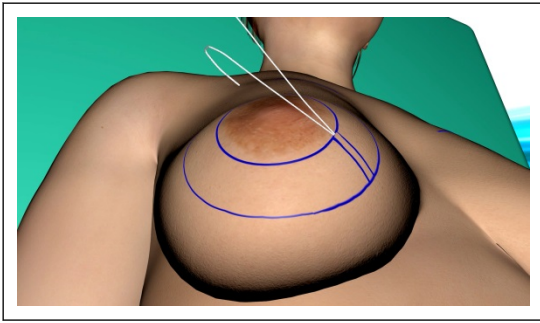


Figure 7: Elastic conization of the breast pushes the implant into contact with the chest wall.

The mammary apex is conized through the same small periareolar incision. If the elastic thread is implanted very close to the margin of the areola, it prevents enlargement of the areola. Turning a rounded breast apex into a pointed one makes the breasts look more youthful (Figure 8).

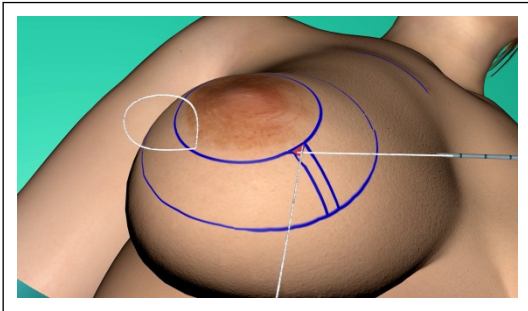


Figure 8: The periareolar elastic thread makes the mammary apex point-like.

After conization, if the breasts are still ptotic, they are suspended by means of an elastic thread to the thoracic subcutaneous tissue at the border with the skin of the breast. To locate this line, the breast is raised while the patient is standing. This elastic thread is implanted through an incision of a few millimeters in the anterior axillary line. After passing through the thoracic subcutaneous tissue, the Jano needle crosses the most prominent portion of the lower quadrant of the breast (Figure 9).

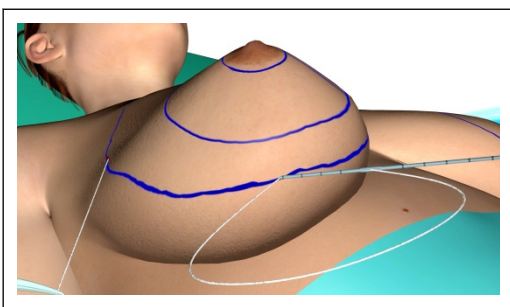


Figure 9: The elliptical elastic suture lifts the breasts, suspending them to the thoracic subcutaneous tissue.

Results

Periareolar conization makes breasts with low- or medium-profile implants look more natural, as it eliminates the artificial roundness that is characteristic of breast augmentation. The areolae no longer tend to enlarge.

Breasts with large implants tend to sag under the weight of the implant, coming to resemble a “ball in a sock”. Elastic conization repositions the implant in contact with the chest wall, widening and compacting the base of the breast (Figure 10). The anterior portion of the breast regains greater mobility. Ptosis is corrected by the elliptical elastic suture.

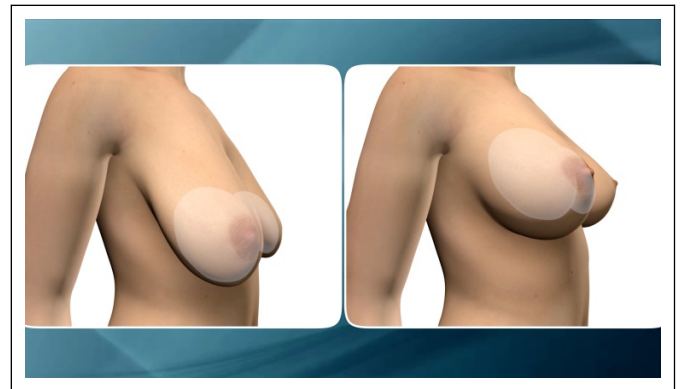


Figure 10: With three elastic sutures and two incisions of a few millimeters, it is possible to improve the appearance of breasts with implants.

The results of elastic conization and suspension of the breasts remain stable over time.

Discussion

We always do elastic conization after a few months after breast augmentation. Conization is not performed simultaneously in order not to interfere with the healing of the periareolar access that we usually use. Passing the Jano needle at an implantation depth of 5 mm presents no risk. Using implants made of cohesive silicone gel increases the safety of elastic conization. We have no experience with saline implants, as we do not use them. In the 16 patients we have operated on so far, there have never been any complications. Conization does not cause atrophy of the apical tissues of the cone of the breast, even if the patient has already undergone round block with skin removal [7-10] by previous operators (Figure 11). Elastic conization obviates the need to perform round block and avoids scarring around the areola. If there is excess skin, we perform Adipofilling, which involves filling the apex of the breast with small fragments of lobular fat. As for the elliptical elastic suspension suture, this really is capable of permanently lifting the breast. This may appear unlikely, as suspending the breasts by attaching threads to the collarbone or subcutaneous tissue is known to be unsuccessful. Indeed, the suspension threads cut through the collarbone and the tissues. By contrast, our elastic threads are impalpable, do not cut into the tissues, and are transformed into ligaments that become integrated into the

subcutaneous tissue. The elliptical pathway of the suture offers ample fixation both at the top and at the bottom.

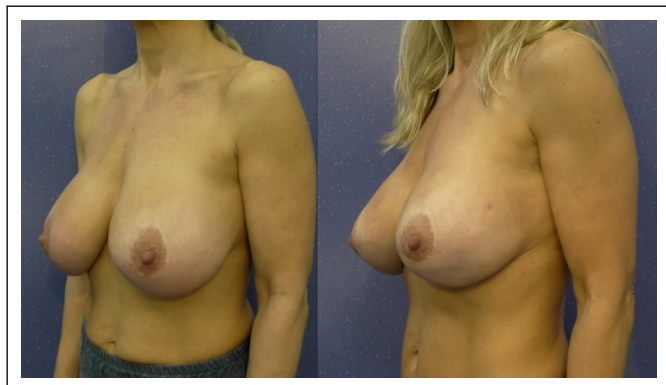

Figure 11: The coned and suspended breasts appear more attractive and natural.

Conclusion

Conization and suspension by means of the elastic thread and the two-tipped needle are procedures that make breasts with silicone implants look more pleasant and natural—an effect that is achieved through only two skin incisions of a few millimeters.

References

1. Capurro S (1984) Elastic plastic surgery. *Italian Journal of Plastic Surgery* 16: 55-58.
2. Capurro S (2004) Patent: Sheathed elastic surgical thread. ITGE20030007 (A1): 7-28.
3. Capurro S (2016) Patent: Non-traumatic two-tipped needle for surgical suture. BRPI0610496 (A2): 11-16.
4. Capurro S. (2020) Mastopexy of drooping breasts with silicone implants, by means of two tiny incisions and elastic threads. CRPUB medical video journal.
5. Capurro S. (2019) Conization and mastopexy of breasts with silicone implants by means of two incisions of a few millimeters and the Elasticum thread and Jano Needle. CRPUB medical video journal.
6. Capurro S. (2017) Conization of breasts that have silicone implants by means of the elastic thread and Jano needle. CRPUB Medical Video Journal.
7. Fogli A (1990) [Indications and limitations of breast lifting by peri-areolar approach (round block). Report of 48 cases]. *Ann Chir Plast Esthet* 35: 459-469.
8. Benelli L (1990) A new periareolar mammaplasty: the "round block" technique. *Aesthetic Plast Surg* 14: 93-100.
9. Swanson E (2022) The Limitations of Periareolar Mammaplasty. *Plast Reconstr Surg Glob Open* 10: e4068.
10. Kim MK, Kim J, Jung SP, Bae SY, Choi MY (2013) Round block technique without cerclage in breast-conserving surgery. *Ann Surg Oncol* 20: 3341-3347.