

Photodynamic Cosmetic Therapy on Melasma Management - Melan ReduXX Program

Priscila Fernanda Campos Menezes^{1,2*}, Nahdia Jackeline Souza Caixeta¹ and Vanderlei Salvador Bagnato²

Abstract

The melasma has a multifactorial pathogenesis and a lot of strategies on treatment are proposed. However melasma has no a final treatment because depending of hormonal alteration, UV exposition frequently and other causes, the pigmentation comes again and in many cases stronger than before treatment. The aim of this study is to demonstrate that the management of melasma proposed in the melan reduxx program is possible by associating different treatment strategies as: professional procedures on clinical using low level light professional therapy with laser and LEDs, in different visible wavelengths in the presence of chemical and photoactivated peels (professional cosmetics products) as well as home care procedures using topical and oral cosmetics products. The management of melasma can be realized from 3 to 4 months, decreasing the skin pigmentation gradually. The melan reduxx program is proposed to be performed from 5 to 15 sessions with intervals from fifteen to thirty days between sessions. In agreement with the results it is possible to perform the Photodynamic Cosmetic Therapy on melasma management on melan reduxx program using chemical and photoactivated peels with safety and effectivity associating visible light and a lot of cosmetology.

Keywords: Photodynamic cosmetic therapy; Melasma; Laser; Chemical peel; Photoactivated peel

- 1 Belle la Pelle Clinica de Estética & Cursos Profissionalizantes – Araras-Sao Paulo, Brazil
- 2 Instituto de Física de São Carlos (IFSC) – University of São Paulo (USP), Av. Trabalhador São Carlense, Brazil

*Corresponding author:

Dr. Priscila Fernanda Campos Menezes

✉ priscilamene2015@gmail.com

Tel: 551633739672

Instituto de Física de Sao Carlos (IFSC), University of Sao Paulo (USP), Av. Trabalhador Sao Carlense, 400 - CEP: 13560-970; Sao Carlos - Sao Paulo, Brazil.

Received: July 11, 2020; **Accepted:** August 05, 2020; **Published:** August 12, 2020

Introduction

One of the most frequently asked questions from patients to aesthetic health professionals is about the effective treatment of melasma. The answer to this question is "No," because melasma has no treatment but management. This means that melasma may be controlled, but at some point either by hormonal fluctuation, sun exposure and some kind of aggression in the skin that triggers an inflammatory reaction, it may come back more stronger with a lot of amount of melanin formed in the region (pigment rebound effect) [1-3]. Then we can say that the management of melasma can be defined as a treatment for all life.

Melasma has a multifactorial pathogenesis that involves the Genetic predisposition, hormonal factors, pregnancy, ultraviolet (UV) radiation exposure frequently, farmaceutical drugs and cosmetics on skin, that play important role on increase in melanin deposition in the epidermis and dermis (epidermal and dermal melasma) [1,3-6].

During pregnancy, increased levels of estrogen and progesterone, that stimulates the alfa MSH receptor, increases the pigmentation

on skin. The oral contraceptives also have been linked to skin hyperpigmentation since that increases the levels of estrogens stimulating the activity of melanocytes. On postmenopausal the levels of estrogen also increase by aromatase enzyme activity also stimulating the pigmentations on skin melasma. The patients with melasma shows in all stituation an increased expression of estrogen receptors at skin and many strategies has been done to act on selective estrogen receptor modulators – SERMs [7,8].

In this sense, some depigmenting active principles, even by different mechanisms, have as their final objective the decrease of spots and melasma on skin acting by different mechanisms as: promoting the degradation of superficial melanin on skin (peelings effect); inhibition of melanin production on skin by tyrosinase enzyme (melanogenese modulation); destruction of melanocytes by autophagy mechanisms; and also interfering on

transportation of melanin from melanosomes to keratinocytes.

In this sense, some depigmenting cosmetics actives, even by different mechanisms, have as their final objective the decrease of spots and melasma on skin acting by different mechanisms as: degradation of superficial melanin (peelings effect), inhibition of the melanin production through melanogenesis pathways control (tyrosinase enzyme activity inhibition), destruction of the melanocytes by autophagy mechanism; decreasing of the melanin granules transportation from melanocytes to keratinocytes, reduction of proinflammatory effects (antioxidant agents), decreases of the number of vessels on skin and finally by hormonal modulation of estradiol hormone [1,9-11].

Professional procedures for melasma treatment are summarized as: chemical (acid) peels, mechanical (abrasive) peels, electric peels, High-power laser therapy, intense pulsed light (IPL) and more recently the Low-level light therapy, using laser and LEDs, both therapies associated with professional and home care cosmetics [5,6]. Chemical peels act by accelerating the renewal of cells on surface and deep layers of the skin. High Power Laser Therapy and intense pulsed light acts by selective photothermolysis mechanism. Mainly Chemical peels and High Power Laser Therapy are widely used in clinical practice, but have a high rate of rebound pigmentation effect as they lead to post inflammatory hyperpigmentation (HPI) common to extremely sensitive skin with melasma [3,11-13].

In a deal with the literature there are a great number of cosmetics actives (topical and oral) that acts on melanogenesis pathways control. The best topical cosmetic actives found to melasma treatment can be described as: vitamin C, alpha arbutin, arbutin, kojic dipalmitate, kojic acid, curcumin, resveratrol, epidermal growth factor, fibroblast growth factor, TGP-2, retinol microspheres (cosmetic retinol like), mandelic acid, tranexamic acid, niacinamide, Hexylresorcinol, arbutin, belides, alpha arbutin, ferulic acid, phytic acid, prodizia, among others [14-17].

One of the latest technological developments in topical melasma treatment is the cysteamine active. Cysteamine is a reducing molecule, endogenous antioxidant, and this molecule is able to act on the enzymes responsible for the formation of melanin by modulating melanogenesis. Tyrosinase and peroxidase sequester iron and copper does not let the free H_2O_2 pre-radical react with iron and form the Fenton reaction, a reactive oxygen species generator that stimulates the entire melanogenesis pathway [14,15].

For oral cosmetic defined as nutraceuticals we summarized as: Pycnogenol, hydroxytyrosol, polypodium leucotomos, resveratrol, panax ginseng, nicotinamide, vitamin c, curcumin, panax ginseng, green tea, zinc chelate, melatonin, tranexamic acid, among others [16-18].

The most common strategies on melasma Management are to modulate inflammation, vascularization that "nourish" melasma, formation and transfer of melanin formed in the skin as well as cosmetic-like hormonal modulation. For this to occur safely and effectively the combination of low power light with laser and LEDs is necessary. Management of melasma should be performed

using minimally invasive professional aesthetic treatments, ie, those that have modulation of the inflammatory response as well as the use of topical and oral home care cosmetic products such as nutraceuticals [3,16-18].

Therapy of photobiomodulation (PBM) is the best technical term for Low Level Laser Therapy (LLLT). It is a light therapy using lasers or LEDs to improve tissue repair, reduce pain and inflammation in the most frequently applications. Many clinical studies on pain with Photobiomodulation applications have been published. Photobiomodulation has been used for many years on sports injuries, arthritic joints, neuropathic pain syndromes, back and neck pain. Nowadays the photobiomodulation in dermatology is increasing since that PBM accelerates the healing of wounds (traumatic, surgical, acute, and chronic) as well as can be useful on cutaneous wounds and accelerating healing after aggressive aesthetic treatments (high power laser therapy and chemical peels procedures). also the pbm has a lot of application on aesthetic and dermatological approach for aging treatment, acne, spots, alopecia and other applications [6,18,19].

Low level light professional therapy using lasers and LEDs for professional uses can be useful to practitioners to performing various skin treatments for aesthetic and dermatological purposes [5,6,18-20].

In our previous paper we defined photodynamic cosmetic therapy (PDT) as a mixture between Phototherapy (now called Photobiomodulation Therapy) and Photodynamic Therapy behavior since that uses low power light radiation (mW) and low-medium light irradiation dose or fluences (J/cm^2) in the presence of photoactives [3,18,21].

Also we defined photocosmetic as products that present chromophores photostable on its formulations capable to induce photophysical and photochemical mechanism to promote photobiological effects on the tissue [18,21]. The photocosmetic product contains photoactivated actives associated with other cosmetic components on formulation depending on cosmetic goal [3,18,21].

Photoactivated Peels, on the other hand, is defined as a cosmetic composition contend chemical peels (such as glycolic acid, salicylic acid, lactic acid, mandelic acid) in low concentrations (cosmetic proposes) associated with actives that increase light absorption in the skin called as photoactives, promote the Peeling effect in a controlled manner without distancing patient's from professional and social life [3,18,21]. This photoactives used as methylene blue (absorbs light on 630 nm- red region), curcumin (which absorbs light on 450 nm – blue region), hypericin (which absorbs light in the region of 590 nm - yellow/amber - region) increase the light interaction of skin. Others photoactives or photosensitizers can be found on the literature on Photodynamic Therapy applications on cancer and dermatology skin diseases [3,18,21].

Finally, the Photoactivated Peels can be defined as less aggressive and non-invasive cosmetic formulations, and can be performed by non-medical aesthetic professionals with safe and effective results. Chemical peels associated with visible light on procedure can be applied also with safety [18].

Managing melasma with light consists of applying different laser/LED wavelengths (colors) acting on all signaling pathways of melanin formation in the skin. Then Amber led light acts: stimulating the degradation on superficial to deep melanin on skin; stimulate melanin autophagy; generate local vasoconstriction decreased vascularization; as well as modulating the inflammatory process; main responsible for the “rebound effect”; increases of spots after treatment [22-27].

Also the Red light decrease the melanogenesis process since that decreases the tyrosinase enzyme activity as well as contributes to modulating the aging on dermis, induced by sun (photoaged skin), that have impaction on several inflammatory mediators such as endothelin-1, stem cell factor, c-kit, GM-CSF, iNOS, and VEGF, besides having a greater number of inflammatory cells and vessels, have been described as more highly expressed in skin with melasma, when compared to normal adjacent skin. The red light has a greater influence on dermis structuration stimulating proliferation of fibroblast that increases collagen and other proteins on dermis layers modulating also the inflammatory response of damaged skin [28-30].

Blue LED light in low fluences acts also decreasing the pigmentation by different mechanism as: inhibits melanin synthesis, promoting degradation on superficial melanin and also improves of the hydration of skin optimizing the reversion of aging on skin [31,32]. The infrared light acts modulating also de inflammatory response corroborating to melasma treatment. The Microneedling technique is a promising technique for transdermal drug delivery and on melasma treatment acts optimizing the permeation of cosmetic actives on skin and also improves the liberation of growth factors decreasing the aging process [33].

The aim of this study is to demonstrate that the management of melasma proposed in the melan reduxx program is possible by associating different treatment strategies as: (1) application of Low level light professional therapy, using laser or LED, on different visible light wavelengths, (2) professional cosmetics, including chemical and photoactivated peels and (3) topical and oral cosmetics (nutraceuticals) for home care applications. So, it is possible to perform the Photodynamic Cosmetic Therapy on melasma treatment using chemical and photoactivated peels on aesthetical procedures with safety and effectivity associating visible light and a lot of cosmetology.

Materials and Methods

Equipment

The laser and LED light treatment was done using commercial equipment called Venus (MM Optics - São Carlos-Brazil). The equipment shows red and infrared laser light on 630 nm and 850 nm respectively and blue and Ambar LED light on 450 nm and 590 nm. In **Figure 1** the irradiation procedure at skin can be observed using different wavelengths and in the **Figure 2** we can observe the melasma diagnosis.

Volunteers

The case report for melasma was carried with female volunteers

with age from 30 to 40 years old, healthy (without any concomitant disease), skin phototype III and IV, with melasma on face, characterized by elevated pigmentation. The volunteers were clarified about the study and read and signed the informed consent, authorizing the accomplishment of the procedures. The patients report years of problems with many tries with conventional therapy without satisfactory results.

Melan Redux Program - Melasma management

The melan reduxx program; on melasma management is possible by associating different treatment strategies as: professional procedures on clinical using low level light professional therapy, with laser and LEDs, in different visible light wavelengths in the presence of chemical and photoactivated peels (professional cosmetics products) as well as home care procedures using topical and oral cosmetics products. The management of melasma can be realized from 3 to 4 months until 5 months, decreasing the skin pigmentation gradually.

The professional treatment using chemical and photoactivated peels is proposed to be performed from 5 to 15 sessions with intervals from fifteen to thirty days enter sessions. However the spots on skin beginning decrease with one month after melan reduxx program initiation. This program can be used on epidermal



Figure 1 Photobiomodulation professional session on Melasma management. The equipment used on study is called Venus (MMOptics – São Carlos- Brazil).

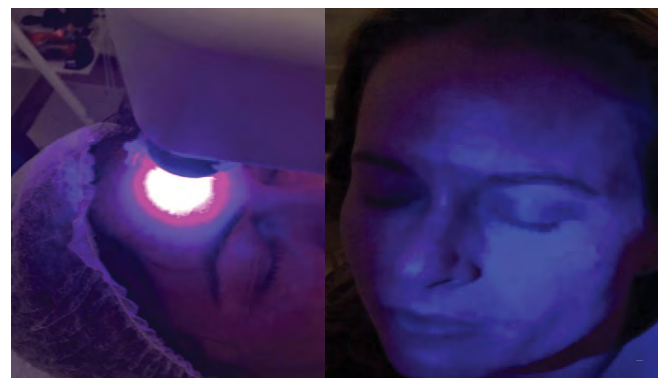


Figure 2 Melasma diagnosis using commercial equipment called EVINCE (MMOptics – São Carlos- Brazil).

and dermal melasma. In case of dermal melasma is possible to associate collagen biostimulation technics invasive (PDO THREADS, calcium hydroxyapatite, Poly-L-lactic acid (Sculptra) and non-invasive (microneedling, deep and medium peelings) associated to melan reduxx program.

Melasma resistant in most of case with hormonal causes and melasma resistant to hydroquinone must be evaluated in relation to good professional practice. on first case is important to evaluate the estrogen in hormonal exames and perform the hormonal modulation with nutraceuticals as melatonin, chrysin and others. and in the second case trying to work with topical cysteamine (epidermal melasma) and topical and oral cosmetics formulations (nutraceutical) with elevated antioxidant proposal.

It is important to mention that hormonal fluctuations, excessive solar radiation, photosensitizing medications can lead to increased skin pigmentation. And each case should be discussed with the aesthetic health professional to evaluate the best strategies that minimize the rebound effect of pigmentation on melasma [14,17].

The melan reduxx program can be carried out for 3 until 5 months throughout the year with annual maintenance or as needed. However topical and oral cosmetics should be kept under continuous use; since these are nutraceuticals that aim to modulate antioxidant stress due to external factors (UV radiation among others), inflammation as well as excessive vascularization of the skin and the hormonal factors present (estrogen modulation due to different causes with herbal medicines). The melan reduxx program can be performed in men and women who have melasma both epidermal and dermal melasma.

Melan Reduxx Program - Professional procedure

The melan reduxx program involves the application of chemical and photoactivated peels and application of low level light professional therapy using amber LED (25 J/cm²) and infrared laser light (5 J/cm²) associated on irradiation procedure (total dose= 30 J/cm²). The application of both wavelengths at same time is useful modulating mainly the inflammatory response [34]. Not forgetting the benefits of amber LED light on decrease of vascularization and degradation of melanin.

On melan redux procedure firstly to open skin we can use tools as microneedling and chemical peels. This first step (FASE 1) increase the permeation of the photoactivated peels thought skin on FASE 2.

On the second step (FASE 2) the photoactivated peel, commercial professional cosmetic called melan reduxx peel (Priscila Menezes company – Araras- Brazil) was applied on skin and immediately after; started the light irradiation procedure, using laser and LED, at skin.

The melan reduxx Peel cosmetic (photoactivated peel) presents on its composition a blend of AHAs (mandelic acid, lactic, glycolic acid) and BHAs (salicylic acid) at low concentrations, photoactives (chromophores) as hypericin (0.5-1%), methylene blue (0.05-1%) and curcumin (0.5-1.5%), that absorbs amber, red and blue light respectively, associated with tranexamic acid (2-8%) and others

principal actives that acts on depigmenting skin as arbutin, alpha arbutin, kojic acid, resveratrol, vitamin c, dipalmitate, kojic acid, niacinamide, Hexylresorcinol, belides, ferulic acid, phytic acid, prodizia and others.

After irradiation procedure the photoactivated peel was removed from skin and a third cosmetic product, in the form of a mask, was added at skin. This mask contains a blend of actives and cosmetic retinol. This mask must remain on the skin until 8 hours on skin. All these products are used in the professional procedure on clinical [14-17].

Oral and topical home care cosmetic products

For topical cosmetic proposals of the melan redux program on home care melasma management; we development commercial cosmetics products (Priscila Menezes company – Araras- Brazil) and them can be described as nutri skin Advanced cream (anti-aging cream), melan clean cream (depigmenting cream), Irradiance eyes cream (depigmenting cream of eyes) and hidra balance Advanced cream (High moisturizing and inert cream). The melasma cosmetic kit (Priscila Menezes company – Araras - Brazil) proposed here contains the follow creams: nutri skin advanced, melan clean and hidra balance advanced. the application of products must be done in the follow sequence; 1) on morning must be applied on skin firstly nutri skin advanced cream on face and after one sunscreen and 2) at night must be applied on skin firstly the melan clean cream on all face. the topical commercial formulations contains the principal cosmetic actives as mentioned before, that acts on melanogenesis pathways control as well as on aging process, on hydration and restoring the skin barrier (protection of skin) [15,17]. one another nocturnal formulation containing acid can be prescribed to be added after melan clean cream only over spots. This formulation can be similar to kligman formulation containing retinoic acid, hydrocortisone and actives as kojic acid, mandelic acid and arbutin in the place of hydroquinone.

The oral cosmetic substances used on melan reduxx program can be described as : Picnogenol (50-100 mg), hydroxytyrosol (100-300 mg), polypodium leucotomos (100-200 mg), resveratrol (20-100 mg), panax ginseng (50-200 mg), nicotinamide (50-200 mg), vitamin C (50-200 mg), curcumin (50-250 mg), green tea (50-200 mg), zinc chelate (10-50 mg), chrysin (100-500 mg), bioperine (5-10 mg) among others. Also melatonin (medical prescription: 3-10 mg) and oral tranexamic acid for patients without thrombo problems (medical prescription 250 mg) can be prescribed by doctors [3,16,17].

Both topical and oral cosmetic products on The melan reduxx program has intention to controlling skin pigmentation by different strategies and modulating the inflammatory process avoiding the rebound effect due to hyperpigmentation pos inflammatory so common on melasma treatment.

Discussion

In **Figure 1** light application on skin using laser and LEDs systems on different wavelengths was performed on melasma patient.

In **Figure 2** the melasma diagnosis is performed using equipment called Evince. The evince equipment has violet visible light on 405 nm (visible light wavelength) differently from wood lamp, which presents black light (ultraviolet light wavelength) which is a disadvantage; can be useful on diagnosis of epidermal and dermal melasma.

The volunteer in **Figure 3** was submitted to photobiomodulation professional session using only amber LED light associated to infrared laser light only in a side of face (left side). As we can see the PBM procedure decreases the pigmentation on skin (C-D).

The irradiation with amber LED light decreases the pigmentation on skin since that decreases the inflammation and vascularization of skin as well as increases the degradation of melanin at skin [27,35-38]. However is important to mention that many authors mention about the photooxidation effects of melanin on skin by visible light increasing either oxygen reactive species than skin pigmentation [35-38].

In case after visible light irradiation procedure the skin pigmentation decreases by bleaching from amber LED light (visible light). But the melanin production after one week can be increased as protection mechanism [37,38]. Knowing this, the application of ideal home care after the melan reduxx program procedure is very important avoiding the melanogenesis activation and as consequence increase of skin pigmentation. In this way in our studies we associate amber LED light to infrared laser light modulating the inflammatory response.

The association of the infrared laser light to amber Led light on irradiation procedure; avoids the post inflammatory hyperpigmentation after procedure; since that amber led light degraded the melanin on skin and when associated with infrared light; the modulation of inflammation occurs avoiding the feedback negative. In the **Figure 4** both patients used only the cosmetic home care during 90 days of treatment. However the Patient on **Figures 4A and 4B** used topical (Melasma Kit - Priscila Menezes Company – Araras- Brazil) and oral (nutraceuticals) home care cosmetics. On **Figures 4C and 4D** the patients used only topical (Melasma Kit - Priscila Menezes Company – Araras-Brazil) home care cosmetics. As we can see the treatment using only home care cosmetic products show good results on skin depigmentation. But the association between oral and topical cosmetics on home care applications; improve the results on skin aging and on pigmentation control (**Figures 4A and 4B**).

In **Figure 5** the patient was submitted to one session of Melan Reduxx procedure using laser and LEDs in the presence of chemical and photoactivated peels (Priscila Menezes company – Araras- Brazil) associated with topical home care cosmetics (Melasma Kit - Priscila Menezes company – Araras- Brazil) around 90 days of treatment. This patient was diagnosticated with dermal melasma by equipment EVINCE (MMOptics-Sao Carlos-Brasil) and the hormonal dysfunctions influences was evaluated on the anamnesis form. The results shows that the pigmentation of skin decreases very slowly, but for only one treatment session, using only the topical home care cosmetics around 90 days, the results were excellent.

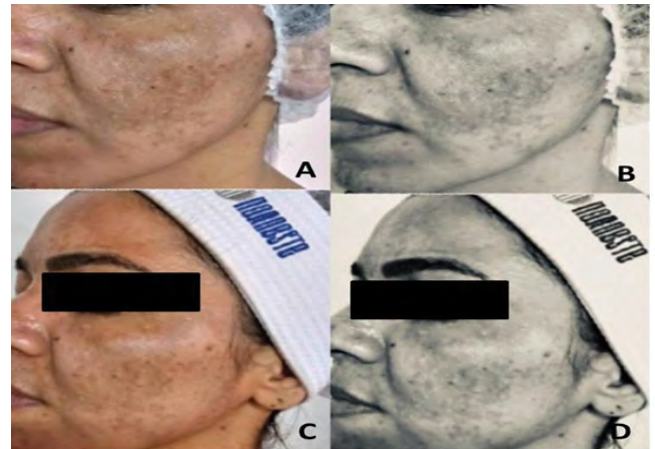


Figure 3 Patient submitted to one Photobiomodulation professional session using only amber LED light associated to infrared laser light only in a side of face (left side). The fluency applied on skin was 30J/cm². Before treatment (A-B) and after treatment (C-D).

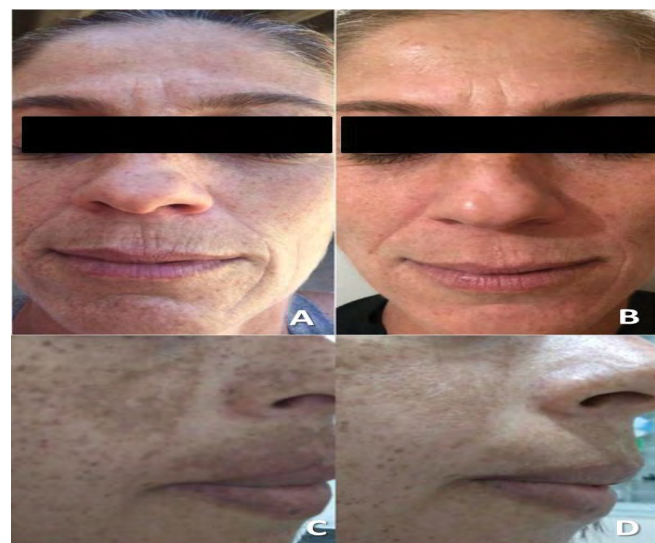

Figure 4 Patient submitted to topical and oral home care cosmetics. Patient on Figure 4A and 4B used topical (Melasma Kit - Priscila Menezes company – Araras-Brazil) and oral (nutraceuticals) home care cosmetics. On Figures 4C and 4D the patients used only the topical (Melasma Kit - Priscila Menezes company – Araras- Brazil) home care cosmetics. Before treatment (A-C) and after treatment (B-D).

Already on **Figures 6, 7 and 8** the Patient was submitted to four session of melan reduxx procedure using laser and LEDs in the presence of chemical and photoactivated peels (Priscila Menezes company – Araras- Brazil), associated with topical (Melasma Kit - Priscila Menezes company – Araras- Brazil) and oral (nutraceuticals) home care cosmetics treatment. The treatment was done on four sessions with an interval from 15 to 30 days between the sessions (from 3 to 5 months of complete treatment).

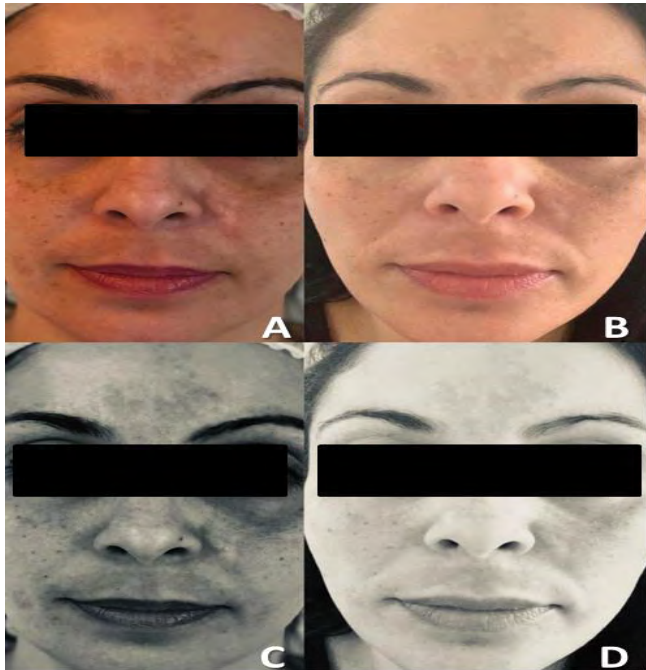


Figure 5 Patient was submitted to one session of melan redux procedure using laser and LEDs in the presence of chemical and photoactivated peels (Priscila Menezes company – Araras- Brazil) associated with topical home care cosmetics (Melasma Kit - Priscila Menezes company – Araras- Brazil). The fluency applied on skin was 30J/cm². Before treatment (A-C) and after treatment (B-D).

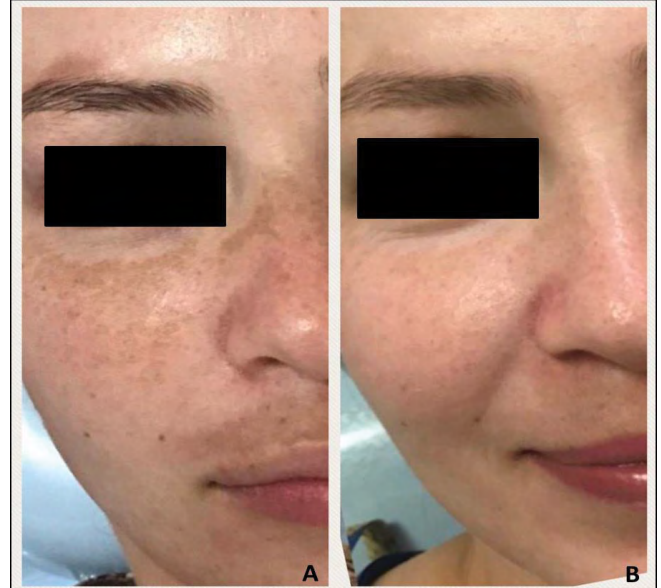


Figure 7 Patient was submitted to four sessions of melan redux procedure using laser and LEDs in the presence of chemical and photoactivated peels (Priscila Menezes company – Araras- Brazil) associated with topical (Melasma Kit - Priscila Menezes company – Araras- Brazil) and oral home care cosmetics treatment. The four sessions were performed with an interval of 15 days between sessions. The fluency applied on skin was 30J/cm² using amber LED light associated to infrared laser light. Before treatment (A) and after treatment (B).

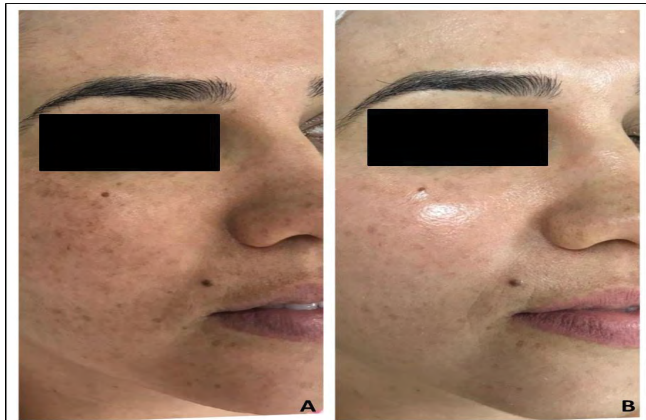


Figure 6 Patient was submitted to four sessions of melan redux procedure using laser and LEDs in the presence of chemical and photoactivated peels (Priscila Menezes company – Araras- Brazil) associated with topical (Melasma Kit - Priscila Menezes company – Araras- Brazil) and oral (nutraceuticals) home care cosmetics treatment. The four sessions were performed with an interval of 15 days between sessions. The fluency applied on skin was 30J/cm² using amber LED light associated to infrared laser light. Before treatment (A) and after treatment (B).

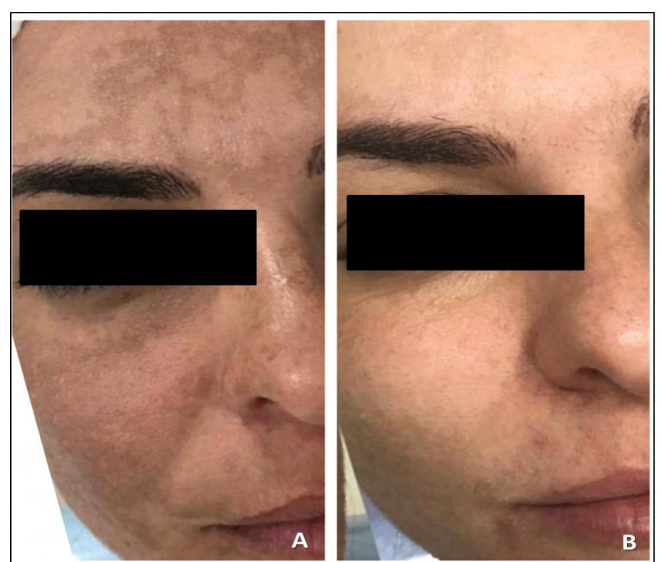


Figure 8 Patient was submitted to four sessions of melan redux procedure using laser and LEDs in the presence of chemical and photoactivated peels (Priscila Menezes company – Araras- Brazil) associated with topical (Melasma Kit - Priscila Menezes company – Araras- Brazil) and oral (nutraceuticals) home care cosmetics treatment. The four sessions were performed with an interval of 15 days between sessions. The fluency applied on skin.

In a deal with results presented on melasma management when we applied only light irradiation using LED and LASER on procedure

(Figure 3), only home care cosmetics products (Figure 4) as well as just one professional session even associated with home care cosmetology (Figure 5) the depigmentation of melasma occurs slowly when compared with all the results showed on the Figures 6, 7 and 8 where the melan redxxx program was performed. It is important to emphasize that the melan redux program must be performed considering at least 5 session of procedure until 10 or 15 session to keeping the pigmentation on melasma at skin under control. We also highlight that there is a great importance of maintaining home care treatment after treatment in the clinic so that the results are longer lasting.

Conclusion

In agreement with the results it is possible to perform the photodynamic cosmetic therapy on melasma management

proposed here in the melan redxxx program associating different treatment strategies as: application of low level light professional therapy using laser or LED light, in different visible wavelengths, professional cosmetics, including chemical and photoactivated peels and topical and oral (nutraceuticals) home care cosmetics. We also highlight that there is a great importance of maintaining home care treatment after treatment in the clinic so that the results are longer lasting.

Disclosure Statement

The authors inform that there is not conflict of interest.

Acknowledgements

The authors would like to thanks to FAPESP for the financial support for this research.

References

- Lozer PE, David RB (2014) Melasma: Uma abordagem nutricional. *Rev Bras Nutr Clin* 29(1): 86-90.
- Kim M, Kim SM, Kwon S, Park TJ, Kang HY (2019) Senescent fibroblasts in melasma pathophysiology. *Exp Dermatol*. 28(6): 1-4.
- Menezes PFC, Requena MB, Bagnato VS (2014) Optimization of photodynamic therapy using negative pressure. *Photomed Laser Surg* 32(5): 296-301.
- Pillaiyar T, Manickam M, Jung SH (2017) Downregulation of melanogenesis: drug discovery and therapeutic options. *Drug Discov Today* 22(2): 282-298.
- Barolet D (2018) Photobiomodulation in dermatology: harnessing light from visible to near infrared for medical and aesthetic purposes. *Med Res Arch* 6(1): 2-30.
- Barolet D (2018) Dual effect of photobiomodulation on melasma: downregulation of hyperpigmentation and enhanced solar resistance-a pilot study. *J Clin Aesthet Dermatol* 11(4): 28-34.
- Stevenson S, Thornton J (2007) Effect of estrogens on skin aging and the potential role of serms. *Clin Interv Aging* 2(3): 283-297.
- Ogbechie-Godec OA, Elbuluk N (2017) Melasma: an up-to-date comprehensive review. *Dermatol ther (heidelb)*. 7(3): 305-318.
- Arora P, Sarkar R, Garg VK (2012) Lasers for treatment of melasma and post-inflammatory hyperpigmentation. *J Cutan Aesthet Surg* 5(2): 93-103.
- Tse TW, Hui E (2013) Tranexamic acid: an important adjuvant in the treatment of melasma. *J Cosmet Dermatol*. 12(1): 57-66.
- Couteau C, Coiffard L (2016) Overview of skin whitening agents: drugs and cosmetic products. *Cosmetics* 3: 27.
- Sarkar R, Gokhale N, Godse K, Ailawadi P, Arya L, et al. (2017) Medical management of melasma: a review with consensus recommendations by indian pigmentary expert group. *Indian J Dermatol* 62(6): 558-577.
- Trivedi MK, Yang FC, Cho BK (2017) A review of laser and light therapy in melasma. *Int J Womens Dermatol*. 3(1): 11-20.
- Farshi S, Mansouri P, Kasraee B (2018) Efficacy of cysteamine cream in the treatment of epidermal melasma, evaluating by Dermacatch as a new measurement method: a randomized double blind placebo controlled study. *J Dermatol Treat* 29(2): 182-189.
- Kumari S, Thng S, Verma N, Gautam H (2018) Melanogenesis Inhibitors. *Acta Derm Venereol* 98(10): 924-931.
- Zhou LL, Baibergenova A (2017) Melasma: systematic review of the systemic treatments. *Int J Dermatol* 56(9): 902-908.
- Grimes PE, Ijaz S, Nashawati R, Kwak D (2018) New oral and topical approaches for the treatment of melasma. *Int J Womens Dermatol* 5(1): 30-36.
- Menezes PFC, Junior NM, Mata R (2018) Photobiomodulation and photodynamic cosmetic therapy on hair growth: case report. *Clin Dermatol: Res Ther* 1(3): 123.
- Menezes PFC, Requena MB, Lizarelli RFZ, Bagnato VS (2015) Blue LED irradiation to hydration of skin. *Proc SPIE Int Soc Opt* 9531.
- Hamblin MZ (2016) Photobiomodulation or low-level laser therapy. *J Biophotonics* 9(11-12): 1122-1124.
- Menezes PFC, Bernal C, Imasato H (2007) Photodynamic activity of different dyes. *Laser Physics* 17(4): 468-471.
- Bernal C, Ribeiro A, De Andrade G (2015) Photodynamic efficiency of hypericin compared with chlorin and hematoporphyrin derivatives in hep-2 and vero epithelial cell lines. *Photodiag photodyn ther* 12(2): 176-185.
- Oh IY, Kim BJ, Kim MN, Kim CW, Kim SE (2013) Efficacy of light-emitting diode photomodulation in reducing erythema after fractional carbon dioxide laser resurfacing: a pilot study. *Dermatol Surg* 39(8): 1171-1176.
- Alster TS, Wanitphakdeedecha R (2009) Improvement of postfractional laser erythema with light-emitting diode photomodulation. *Dermatol Surg* 35(5): 813-815.
- Lan CC, Ho PY, Wu CS (2015) LED 590 nm photomodulation reduces UVA-induced metalloproteinase-1 expression via upregulation of antioxidant enzyme catalase. *J Dermatol Sci* 78(2): 125-132.
- Mota LR, Motta LJ, Duarte IDS (2018) Efficacy of phototherapy to treat facial ageing when using a red versus an amber LED: a protocol for a randomised controlled trial. *BMJ Open* 31;8(5): e021419.
- Chen L, Xu Z, Jiang M (2018) Light-emitting diode 585nm photomodulation inhibiting melanin synthesis and inducing autophagy in human melanocytes. *J Dermatol Sci*. 89(1): 11-18.

- 28 Kwon SH, Na JI, Choi JY (2019) Review Melasma: Updates and perspectives. *Exp Dermatol* 28: 704-708.
- 29 Oh CT, Kwon TR, Choi EJ, Kim SR, Seok J, et al. (2017) Inhibitory effect of 660-nm LED on melanin synthesis in in vitro and in vivo. *Photodermatol Photoimmunol Photomed* 33(1): 49-57.
- 30 Handel AC, Miot LD, Miot HA (2014) Melasma: a clinical and epidemiological review. *An Bras Dermatol* 89(5): 771-782.
- 31 Vandersee S, Beyer M, Lademann J, Darvin ME (2015) Blue-violet light irradiation dose dependently decreases carotenoids in human skin, which indicates the generation of free radicals. *Oxid Med Cell Longev* 579675.
- 32 Ohara M, Kobayashi M, Fujiwara H, Kitajima S, Mitsuoka C, et al. (2004) Blue light inhibits melanin synthesis in B16 melanoma 4A5 cells and skin pigmentation induced by ultraviolet B in guinea-pigs. *Photodermatol photoimmunol photomed* 20(2): 86-92.
- 33 Rodrigues PG, Campos de Menezes PF, Fujita AK, Escobar A, Kurachi C, et al. (2015) Assessment of ALA-induced PpIX production in porcine skin pretreated with microneedles. *J Biophotonics* 8(9): 723-729.
- 34 Menezes PFC, Urbaczek AC, Matta RF, Bagnato VS (2020) Photobiomodulation using Amber Led and Infrared Laser to Controlling the Pigmentation and Flaccidity from Skin. *J Aesthet Reconstr Surg* 6(2): 1-8.
- 35 Ito S, Kolbe L, Weets G, Wakamatsu K (2009) Visible light accelerates the ultraviolet A-induced degradation of eumelanin and pheomelanin. *Pigment Cell Melanoma Res* 32(3): 441-447.
- 36 Shosuke I, Kazumasa W, Tadeusz S (2018) Review photodegradation of eumelanin and pheomelanin and its pathophysiological implications photochemistry and photobiology 94: 409–420.
- 37 Chiarelli-Neto O, Baptista M (2016) Photosensitizing properties of melanin upon excitation with visible light *Trends in Photochemistry & Photobiology* 17: 57-68.
- 38 Mahmoud BH, Ruvoilo E, Hexsel CL, Liu Y, Owen MR, et al. (2010) Impact of long-wavelength UVA and visible light on melanocompetent skin. *J Invest Dermatol* 130: 2092-2097.