

DOI: 10.36648/2472-1905.6.3.60

Use of 3D Printing and Virtual 3D Imaging to aid Mandibular Reconstruction: A Low Cost, Easy and Reproducible Methodology at Our Center

Pradeep Goil and Samarth Gupta*

Department of Plastic and Reconstructive Surgery, SMS Hospital, Jaipur, India

*Corresponding author:

Dr. Samarth Gupta

✉ samarth.4@gmail.com

Tel: 919727777026

Department of Plastic and Reconstructive Surgery, SMS Hospital, Jaipur, India.

Citation: Goil P, Gupta S (2020) Use of 3D Printing and Virtual 3D Imaging to aid Mandibular Reconstruction: A Low Cost, Easy and Reproducible Methodology at Our Center. J Aesthet Reconstr Surg Vol.6 No.3:11

Abstract

Introduction: 3D Printing has been a tool which is being vastly employed in various specialities in the field of medicine. Free Fibula Flap is now regarded as the gold standard for reconstruction following oncological mandibular resection. It helps achieve near to normal occlusion and mastication for the patient. However, the results are confounded due to inappropriate estimate of defect or inappropriate angulation of ostéotomy. 3D printing and virtual planning can hence be an effective tool to help in pre planning osteotomies and implant designs. Unfortunately, in developing countries it is expensive and time consuming often requiring technicians to finish the job. We have devised a cheap (less than 35\$), rapid and reproducible method for this process, which can be performed by residents and medical students.

Materials and Methods: Patients were categorised in two groups, one of which underwent Conventional Free Fibula Flap and the other group consisted of those where 3D Printing was used. The study was conducted in the span of 4 years from 2016-2019. Aesthetic and Functional outcome was measured by preoperative and post-operative 3D Scans. Furthermore, the reconstruction time and total operative time was also measured in both these groups.

Results: Comparative study of 3D Scans clearly demonstrated a better aesthetic outcome of 3D Printing and virtual planning group. The modality also helped reduce surgeons' operative time where reconstruction time was 83.9 mins in the Cases group 124 mins in the control group.

Conclusion: 3D printing and virtual 3D Imaging has the potential to improve the quality of mandibular reconstruction giving better aesthetic and functional outcome. Besides, it also reduces the operative time and gives us a chance to use pre operatively designed patient customised implants. 3D printing obviates the need for speculation and gives exact measurements in all dimensions. We believe that this tool should be incorporated often in Free Fibula Flaps for mandibular reconstruction.

Keywords: 3D printing; Free fibula flap; Virtual 3D Imaging

Received: July 17, 2020; **Accepted:** August 06, 2020; **Published:** August 13, 2020

Introduction

Free Fibula Flap is now regarded as the gold standard for reconstruction following mandibular resection for oncological conditions [1,2]. The flap has many advantages; this is owing to the uniform bicortical thickness, density, long vascular pedicle,

adequate vessel size and less donor site morbidity of the Fibular Graft. Nonetheless, it helps achieve near to normal occlusion and mastication for the patient. However, the results are confounded due to inappropriate estimate of defect or inappropriate angulation of ostéotomy. The idea of replacing "like with like"

holds true in all facets of reconstructive surgery, but for bone defects it is of utmost importance.

When we talk about problems of traditional methods of reconstruction we observe that it requires surgeons experience as a guide to accurate planning of the fibular graft. However, this is difficult to control and often the surgeons are met with dissatisfying results. 3D Printing has been a tool which is being vastly employed in various specialities in the field of medicine. It can hence be an effective tool to help in pre planning osteotomies and implant designs. We believed that there needed to be an easy, reproducible as well as cheap technique to employ these techniques to the developing countries and it is when we came up with this methodology at our center.

Materials and Methods

40 patients were categorised in two groups, one of which underwent Conventional Free Fibula Flap and the other group consisted of those where 3D Printing and virtual planning was used. The study was conducted in the span of 4 years from 2016-2020. Aesthetic outcome was measured by pre and post operative pictures measuring the bony landmarks, distance and angle. Furthermore, the reconstruction and the total operative time was also measured in both these groups.

Technique

Process of 3D virtual planning was done by getting preoperative CT SCAN WITH 3D reconstruction, wherein our centre has a 128 slice, Philips Ingenuity Machine.

The images obtained are saved in DICOM format. (Digital imaging and communications in Medicine) The DICOM images are acquired in a pen drive from the CT center. These images are then opened into a "SLICER" software where a STL format file is obtained. This file is saved separately.

The "STL" would then be opened into meshmixer software for editing. The meshmixer software is the place where the virtual planning is done. The 3D images obtained from the CT scans can be edited in this software.

Use of meshmixer software in virtual planning

These 3D Virtual images of the mandible are used to plan and perform simulation osteotomies within the meshmixer software. This can be done by the performing surgeon where he decides the plane of osteotomy according to the lesion. This is demonstrated in **Figure 1**. After getting residual Bone, a normal mandible shape would be created virtually. This can be created by using blocks within the software as demonstrated in **Figure 2**. Once the residual bone is achieved we move towards planning of reconstruction with fibular bone graft.

The osteotomies on the fibula are planned and the fibular image (created within the software using blocks) would then be superimposed on the resected mandible. In this way, accurate bony segments of the fibula bone are measured which would eventually be used as a guide on the table. If only one side is destroyed, mirror imaging can be done to create a symmetrical




Figure 1 Steps of virtual surgery.




Figure 2 The dimensions of the outer and inner borders of fibula control group.

mandible. If both sides are involved then superimposition is done using guiding lines at the infero-lateral border of the proposed mandible.

As shown in **Figures 2-7** we can accurately measure the osteotomy sites. This as described below will be used as a guide in the operation theatre.

Now that the virtual surgery is finished, 3D prints are obtained, first of the diseased mandible, and then of the virtually reconstructed mandible. These models are then autoclaved. Prints of Virtual planning are used as a guide in the theatre. The autoclaved models are used in the operation theatre itself as the patient is being induced. The markings are then re performed on the model using the printed materials as a guide. Measurements for the fibular osteotomies are also confirmed on the side table.

Then we move on to planning of implants.

In case the reconstruction plates are used they would be contoured over the reconstructed 3D model, Pre bending them. This would be done with the help of drills and screws over the model. If mini plates are used, they would be similarly configured

over the corrected model. Using all this information, the surgeon would go forward with the surgery. Mandibular resection would be performed.

The fibular graft would be harvested and markings made for osteotomies over the same as planned before, except that this time it will be on the patient. Everything else remains the same. The graft would then be fixed to the remaining mandible using either reconstruction plates or mini plates.

In the control group osteotomies were made by the help of the CT scan maintaining adequate margins. Osteotomies were performed solely on the basis of surgeons' experience. These segments would then be fixed by reconstruction plates or mini plates. The reconstruction plate would be bent over the fibular segments.

Results

The 40 patients that were taken into the study consisted of the cases group that had 20 patients (12 males and 8 females); and the control group that comprised of 20 patients (14 males and 6 females)

Case distribution in the virtual planning group:

- Ameloblastoma 12
- SCC 4
- Osteonecrosis 4

Distribution in the control group:

- Ameloblastoma 10
- SCC 6
- Osteonecrosis 2
- The control group average age was 41.9 years (Range 8-65)
- The average age in the case group was 43.9 years (Range 23-60)
- The mean Reconstruction time was 83.9 min in the control group and 124 min in the cases group. Paired T test was applied to take the P-value out of the various data observed.
- The reconstruction time is defined as the time taken from incision for Fibula Harvest to completion of anastomosis.
- The total operative time is defined as the total time taken during the entire surgery including resection and reconstruction which was done by two different teams simultaneously.

Table 1 depicts the comparison of reconstruction time and total operative time in cases and control group.

Bony points used for measuring symmetry were:

- Mandibular bony landmarks, bilateral condyle, bilateral gonion, Gnathion.
- Intercondylar distance, inter gonial angle distance and

anteroposterior distance (using a perpendicular line drawn from the mandibular midline to the center point of the intercondylar length) and gonial angle were measured.

Table 2 demonstrates the comparison of difference in mean in genial angle, intercondylar distance, AP difference in the two groups.

Discussion

The free bony tissue transfer has indeed become the gold standard for mandibular reconstruction and fibula bone has been vastly employed in this [1,2]. Free fibula is the workhorse flap for mandibular reconstruction due to its thickness, length, and bone uniformity, which make it the ideal support for implants and a good match for the alveolar ridge [3-7]. 3D printing and virtual planning has changed the course of managing mandibular defects in the last few years. This technique has given improved results in terms of reduced operating time and good aesthetic and functional results [8-10]. Many authors have given a detailed methodology on going through this technique.

Seruya et al. reported significantly decreased flap ischemia time, from 170 to 120 minutes in a series of 10 computer-assisted mandibular reconstructions [11]. Zhang et al. reported virtual surgical planning decreased the duration of ischemia compared to the conventional group.

In our study, results show that both operative times and reconstructive times were shorter in the computer-assisted group compared with the conventional group. The reduction in the operative time would mean less postoperative complications and lesser ischemia time and reduction in costs due to prolonged anaesthesia and recovery.

Another potential benefit of computer-assisted surgery is the improvement of accuracy of mandibular reconstruction [12].

Table 1: Comparison of Reconstruction time and total operative time in cases and control group.

Variables	Reconstruction time	Total operative time
Virtual planning+3D printing	83.9	199.6
Conventional group	124	285.6
P-value	<0.001	<0.001

Table 2: Comparison of difference in mean in genial angle, intercondylar distance, AP difference.

Variables	Mean of Difference in Gonial angle	Mean of Difference in Intercondylar distance	Mean of Difference in Ap distance
Virtual planning+3D printing	2.85	3.05	4.2
Conventional group	4.9	6.12	7.4
P-value	<0.007	<0.001	<0.001

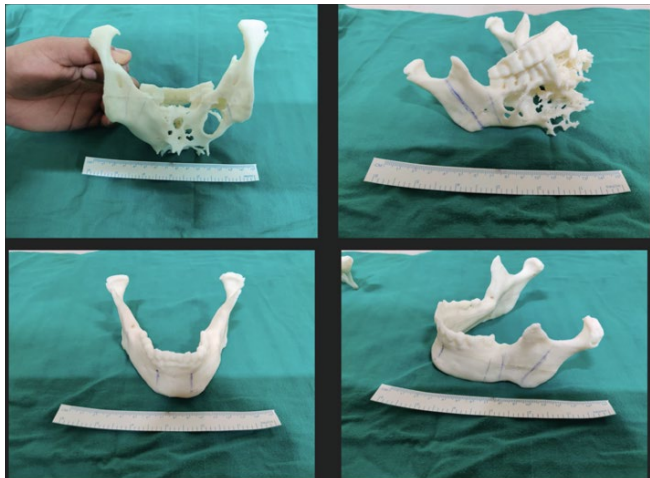

Figure 3 3D prints.

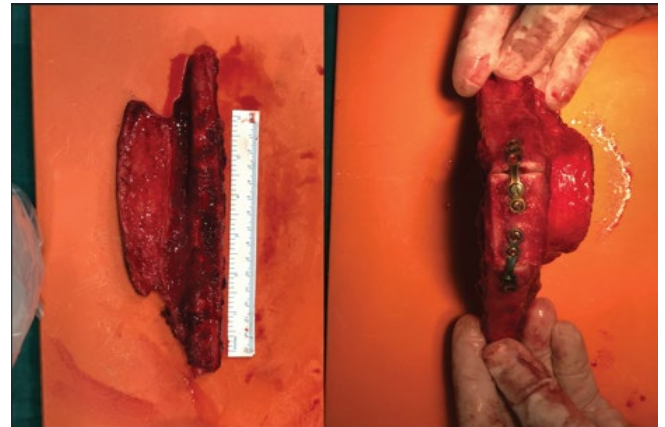


Figure 5 Reconstructed mandible.

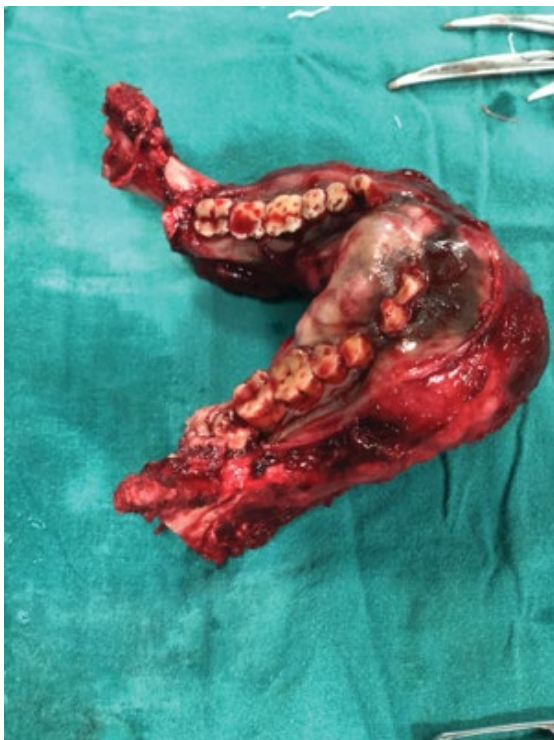

Figure 4 Excised mandible.

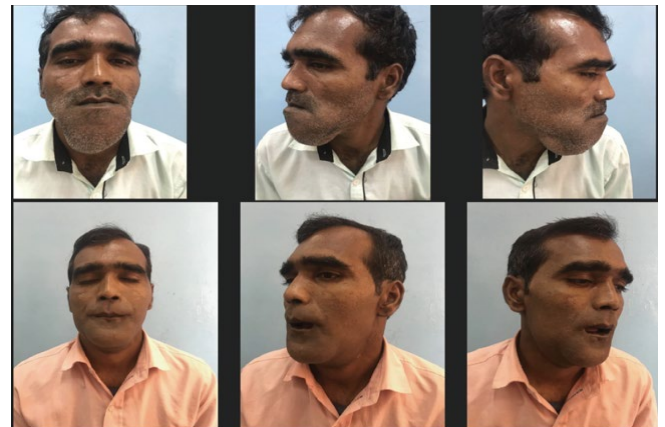

Figure 6 Pre and post-operative pictures.

Accurate planning of mandibular reconstructive procedure using a 3-D model printing was widely described in the literature with satisfactory esthetic and functional outcomes [13]. However, modern techniques used in reconstructive surgery require good cooperation between the radiologist, a team of engineers preparing 3-D model printing as well as the surgeons [14,15].

Additionally, the use of modern technological solutions significantly increases the costs of treatment compared to conventional reconstruction technique [16].

Yao Yu et al. found that combined application of the CAD and surgical navigation resulted in a more accurate outcome for

mandibular reconstruction with free fibula flap [17]. However, time consumption, learning curve and costs should be taken into account when surgical navigation is used as a surgical tool [18].

In a government hospital like ours, we thought that there needed to be a simplification of this process of 3D printing and virtual planning. Therefore we devised a simpler, cheaper and more reproducible method which requires a lesser number of personnel's. The entire process of virtual planning can be performed by the doctor or a working resident. Initially it took 4-5 hours for a beginner to learn about these softwares, but within a matter of a couple of cases the entire planning could be finished in about 2 hours. The use of software is easy and once learnt it can be used in every case that is being posted. 3D prints are readily available nowadays and there are a lot of videos over the web demonstrating on how to make one at home. The overall cost for the entire process was not more than 35\$.

At our centre we could overcome the two main challenges in this technique, namely Cost and Learning Curve.

We also believe that combining virtual planning and 3D printing gives more accuracy to the results as compared to those when used singularly.

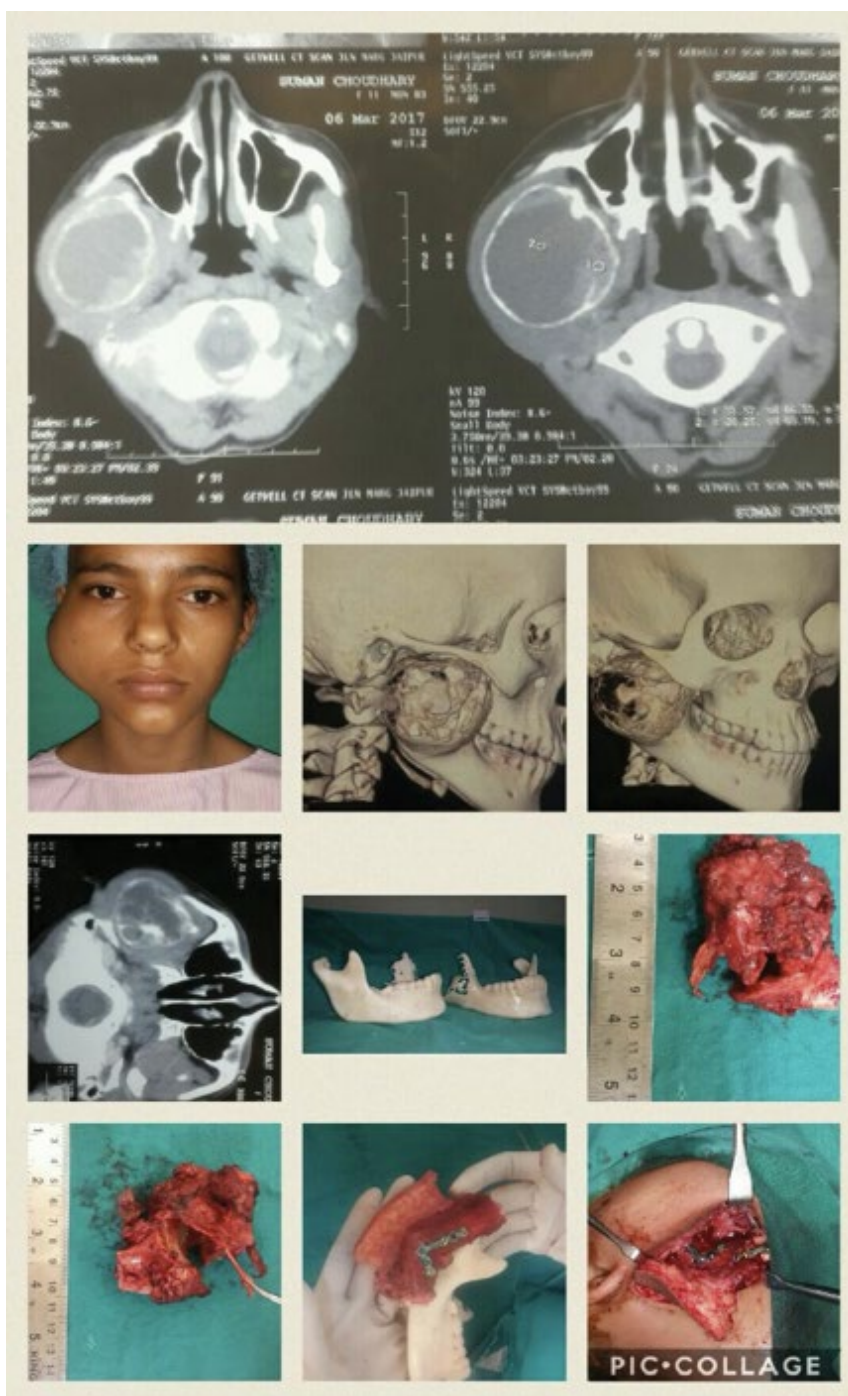


Figure 7 Another case done using this technique.

As per the majority of the studies already described above, our results also show that the mean differences between the preoperative and postoperative intercondylar distances, anteroposterior distances, and gonial angles were smaller in the computer-assisted group compared with conventional group. This demonstrates the accuracy of the technique over conventional methods.

Surgical navigation is a useful tool that can verify the actual position with a preoperative virtual plan during surgery [19]. Based on the fibular transplants, using dental implants for oral

rehabilitation has been frequently used following reconstruction of the mandible and has proven to be a reliable method [20].

Limitations

- The extent of resection in malignant swellings and that of osteoradionecrosis may differ intraoperatively.
- It may change the level of osteotomies and reduce the usefulness of this technique.
- The final outcome can also differ from soft tissue. So this

technique would be best for benign swellings or those having mandibular defects in previously operated cases.

Conclusion

3D printing and virtual 3D Imaging has the potential to improve the quality of mandibular reconstruction giving better aesthetic and functional outcome. Besides, it also reduces the operative

time and gives us a chance to use pre operatively designed patient customised implants. 3D printing obviates the need for speculation and gives exact measurements in all dimensions. Our centre has found a cheap and accessible method to go about this process. We believe that this tool should be incorporated often in Free Fibula Flaps for mandibular reconstruction in developing countries like ours.

References

- 1 Coleman SC, Burkey BB, Day TA, Resser JR, Netterville JL, et al. (2000) Increasing use of the scapula osteocutaneous free flap. *Laryngoscope* 110(9): 1419-1424.
- 2 Hidalgo DA, Pusic AL (2002) Free-flap mandibular reconstruction: a 10-year follow-up study. *Plast Reconstr Surg* 110(2): 438-449.
- 3 Bak M, Jacobson AS, Buchbinder D, Sirjani DB (2010) Contemporary reconstruction of the mandible. *Oral Oncol* 46(2): 71-76.
- 4 Zhang L, Liu Z, Li B, Yu H, Shen SG, et al. (2016) Evaluation of computer-assisted mandibular reconstruction with vascularized fibular flap compared to conventional surgery. *Oral Surg Oral Med Oral Pathol Oral Radiol* 121: 139-148.
- 5 Peled M, El-Naaj IA, Lipin Y, Ardekian L (2005) The use of free fibular flap for functional mandibular reconstruction. *J Oral Maxillofac Surg* 63(2): 220-224.
- 6 Taylor GIAOMD, Corlett RJMD, Ashton MWMD (2016) The evolution of free vascularized bone transfer: a 40-year experience. *Plast Reconstr Surg* 137: 1292-1305.
- 7 Jr FJ, Funk GF, Capper DT, Fridrich KL, Blumer JR, et al. (1993) Osseointegrated implants: a comparative study of bone thickness in four vascularized bone flaps. *Plast Reconstr Surg* 92(3): 456-458.
- 8 Hanasono MM, Skoracki RJ (2013) Computer-assisted design and rapid prototype modeling in microvascular mandible reconstruction. *The Laryngoscope* 123: 597-604.
- 9 Toto JM, Chang EI, Agag R, Devarajan K, Patel SA, et al. (2015) Improved operative efficiency of free fibula flap mandible reconstruction with patient-specific, computer-guided preoperative planning. *Head Neck* 37: 1660-1664.
- 10 Weitz J, Bauer FJ, Hapfelmeier A, Rohleder NH, Wolff KD, et al. (2016) Accuracy of mandibular reconstruction by three-dimensional guided vascularised fibular free flap after segmental mandibulectomy. *Br J Oral Maxillofac Surg*. 54: 506-510.
- 11 Seruya M, Fisher M, Rodriguez ED (2013) Computer-assisted versus conventional free fibula flap technique for craniofacial reconstruction: an outcomes comparison. *Plast Reconstr Surg* 132: 1219-1228.
- 12 Gil RS, Roig AM, Obispo CA, Morla A, Pagès CM, et al. (2015) Surgical planning and microvascular reconstruction of the mandible with a fibular flap using computer-aided design, rapid prototype modelling and precontoured titanium reconstruction plates: a prospective study. *Br J Oral Maxillofac Surg* 53: 49-53.
- 13 Eckardt A, Swennen GR (2005) Virtual planning of composite mandibular reconstruction with free fibula bone graft. *J Craniofac Surg* 16(6): 1137-1140.
- 14 Juergens P, Krol Z, Zeilhofer HF, Beinemann J, Ewers R, et al. (2009) Computer simulation and rapid prototyping for the reconstruction of the mandible. *J Oral Maxillofac Surg* 67(10): 2167-2170.
- 15 Roser MS, Ramachandra S, Blair H, Grist W, Carlson GW, et al. (2010) The accuracy of virtual surgical planning in free fibula mandibular reconstruction: comparison of planned and final results. *J Oral Maxillofac Surg* 68(11): 2824-2832.
- 16 Liu YF, Xu LW, Zhu HY, Sean SY (2014) Technical procedures for template-guided surgery for mandibular reconstruction based on digital design and manufacturing. *Biomed Eng* 13: 63.
- 17 Yu Y, Zhang WB, Liu XJ, Guo CB, Yu GY, et al. (2016) Three-dimensional accuracy of virtual planning and surgical navigation for mandibular reconstruction with free fibula flap. *J Oral Maxillofac Surg* 74(3): 1503.e1.
- 18 Azarmehr I, Stokbro K, Bell RB, Thygesen T (2017) Surgical Navigation: a systematic review of indications, treatments, and outcomes in oral and maxillofacial surgery. *J Oral Maxillofac Surg* 75: 1987-2005.
- 19 Shan XF, Chen HM, Liang J, Huang JW, Zhang L, et al. (2016) Surgical navigation-assisted mandibular reconstruction with fibula flaps. *Int J Oral Maxillofac Surg* 45: 448-453.
- 20 Chana JS, Chang YM, Wei FC, Shen YF, Chan CP, et al. (2004) Segmental mandibulectomy and immediate free fibula osteoseptocutaneous flap reconstruction with endosteal implants: An ideal treatment method for mandibular ameloblastoma. *Plast Reconstr Surg* 113: 80-87.